

*Optometry and Vision Science*

Author's Accepted Manuscript

**Article Title:** Case Report: Spontaneous Closure of Idiopathic Full-Thickness Macular Hole and Early Development of Lamellar Hole

**Authors:** Tozzi L, Gius I, Greggio A, Meduri A, De Salvo G, Parolini B, Rino Frisina

**DOI:** 10.1097/OPX.0000000000002070

This manuscript has been accepted by *Optometry and Vision Science*, but has not been copy-edited. This information is subject to change. Final copy-editing and production will correct errors in language usage and text. Figures and tables may be changed and pages will be composed into their final format.

Visit the journal's website (<https://journals.lww.com/optvissci/>) for the final version of this article.

If citing the article, please follow this example:

Tozzi L, Gius I, Greggio A, et al. Case Report: Spontaneous Closure of Idiopathic Full-Thickness Macular Hole and Early Development of Lamellar Hole. *Optom Vis Sci*:

DOI: 10.1097/OPX.0000000000002070.

## CASE REPORT

### Case Report: Spontaneous Closure of Idiopathic Full-Thickness Macular Hole and Early Development of Lamellar Hole

Luigi Tozzi, MD, Irene Gius, MD, Angelo Greggio, MD, Alessandro Meduri, MD, Gabriella De Salvo, MD, Barbara Parolini, MD, and Rino Frisina, MD

Department of Ophthalmology of San Martino Hospital of Belluno, Belluno, Italy (LT, ), Department of Ophthalmology of University of Padova, Padova, Italy (IG, AG), Department of Biomedical Sciences, Eye Clinic, University of Messina, Messina, Italy (AM), Eye Unit, University Hospital Southampton NHS Foundation Trust, Southampton, United Kingdom (GDS), Eyecare Clinic, Brescia Italy (BP), and Department of Ophthalmology of Guglielmo da Saliceto Hospital of Piacenza, Piacenza, Italy (RF)

**Funding/Support:** None of the authors have reported funding/support.

**Conflict of Interest Disclosure:** None of the authors have reported a financial conflict of interest.

**Study Registration Information:** Not required.

**Author Contributions:** Conceptualization: LT, AG, AM, GDS, BP, RF; Data Curation: LT, IG, AG, RF; Formal Analysis: LT, RF; Supervision: LT, AM, GDS, BP, RF; Validation: BP, RF; Writing – Original Draft: LT, IG, AG; Writing – Review & Editing: LT, RF.

Submitted: January 2, 2023; accepted August 24, 2023.

Corresponding author:

Luigi Tozzi

luigitozzi88@gmail.com Belluno, Italy

Pre-Publication

## ABSTRACT

**Significance:** Spontaneous closure of an idiopathic full-thickness macular hole (FTMH) is a rare event. The underlying mechanisms are unclear due to the difficulty in detecting subtle structural changes even with serial imaging. Previous reports are largely optical coherence tomography (OCT)-based but multimodal imaging could highlight new information.

**Purpose:** to report the spontaneous closure of an idiopathic FTMH (iFTMH), its recurrence and late closure documented by serial OCT integrated with multimodal imaging modalities and microperimetry (MP). **Case report:** A healthy 46 year old man was referred to the department of Ophthalmology of the University of Padova for an iFTMH in the right eye with preserved visual acuity. The patient was scheduled for monthly controls up to 12 months by an integrated assessment of OCT, angiography-OCT (A-OCT), short wave-length fundus autofluorescence (Sw-FAF), MP. Two months later, tracked OCT scans showed a closure of the hole with a residual lamellar macular hole (LMH). Sequential examinations revealed a discontinuation of photoreceptors (EZ), a recurrence of iFTMH and, seven months later, iFTMH re-closed without any relevant changes up to 12 months. Foveal avascular zone (FAZ) area increased from the baseline reaching its maximum value when iFTMH recurred. Two hyper-fundus autofluorescence points were detected in the foveal area, one progressively decreased and one reached the most intense signal when iFTMH recurred. Retinal sensitivity (RS) decreased mostly in one hyper-fundus autofluorescence point when the EZ line discontinued and reached the lowest value when iFTMH recurred, increased mostly in the other points when iFTMH reclosed. **Conclusions:** spontaneous iFTMH closure, its recurrence and reclosure is a rare event. By monitoring with multiple imaging modalities, MP and their overlaying elaboration can add new biomarkers with diagnostic and prognostic value.

Full-thickness macular hole is a vitreoretinal disorder characterized by an anatomical full-thickness defect of the fovea, with interruption of all the neural retinal layers. Surgical repair by pars plana vitrectomy greatly increased the chances of macular hole closure, as pars plana vitrectomy with intravitreal tamponade is recognized as a primary and effective treatment option. The mechanisms leading to the development of full-thickness macular hole and its classification into 4 stages were described by Gass.<sup>1</sup> It was hypothesized that early stages of hole formation are caused by central neuroretinal dehiscence beneath a perifoveolar vitreous cortex contraction followed by centrifugal movement of retinal receptors and xanthophylls at the sides of the impending hole. While spontaneous closure is a common outcome in traumatic full-thickness macular hole, it is unusual in idiopathic macular hole where the incidence ranges from 4 to 11.5%.<sup>2</sup> The mechanisms underlying such a rare event are not fully elucidated. The process leading to the development of full-thickness macular hole and its subsequent spontaneous closure remains a challenge despite frequent follow-up visits. The pivotal events leading to a spontaneous and favourable outcome are unknown. Published studies are largely optical coherence tomography (OCT)-based reports,<sup>2-6</sup> however the mechanisms of closure are not fully known. An abortive process in the development of full-thickness macular hole may lead to lamellar macular hole. Furthermore, the progression of lamellar macular hole with reduction in central foveal thickness or the surgical peeling of a weakened foveal area affected by lamellar macular hole are risk factors for developing a full-thickness macular hole.<sup>7</sup> However, the development of lamellar macular hole following the spontaneous closure of an idiopathic full-thickness macular hole is rare and only a single case report has been published to the best of our knowledge.<sup>8</sup>

In this case report, the natural history of a spontaneous closure of an idiopathic full-thickness macular hole, its recurrence and reclosure detected by multi-modal imaging will be

discussed. The study evaluated the efficacy of a composite elaboration of short wave-length fundus autofluorescence and microperimetry images to estimate the entity of damage seen by a topographical criterion (the superimposed method has been described in a previous published study).<sup>9</sup> Moreover, the meaning of OCT and OCT-angiography changes over time were studied by a quantitative and accurate method to test the retinal sensitivity and the macular function. Comprehensive investigations were performed every month for one year; the abundance of available examinations allowed a better understanding of the events occurring during spontaneous idiopathic full-thickness macular hole closure.

## **CASE REPORT**

A healthy 46-year-old man, employed in an insurance company, was referred to the department of Ophthalmology of the University of Padova complaining of metamorphopsia in his right eye for 2 weeks. He was emmetropic (axial length of the right eye was 23.3 millimeters) and did not report any relevant ocular trauma or previous ocular surgery. An idiopathic full-thickness macular hole was diagnosed in his right eye and its spontaneous closure was observed during follow-up. The patient was scheduled for monthly controls with multiple imaging modalities and functional examinations including OCT and OCT-angiography (RS 3000 Advance, Nidek, Gamagori, Japan), short wave-length fundus autofluorescence (Spectralis; Heidelberg Engineering, Dossenheim, Germany), retinal sensitivity color maps microperimetry (MP3 microperimeter, Nidek, Gamagori, Japan) and superimposed short wave-length fundus autofluorescence/retinal sensitivity color maps.

An overlay of color fundus-related retinal sensitivity map on short wave-length fundus autofluorescence image, acquired at the same time-point of follow-up, was processed using ImageJ software (National Institutes of Health, Bethesda, MD). Retinal vessel bifurcations

were used as landmarks to obtain the exact overlay. Transparency of color fundus microperimetry map was increased to appreciate position of retinal sensitivity tested points on short wave-length fundus autofluorescence image. The detailed composite images allowed for the registration and transfer of retinal sensitivity values from microperimetry to short wave-length fundus autofluorescence image. Short wave-length fundus autofluorescence (excitation: 488 nm, emission >500 nm) images were acquired using a confocal scanning laser ophthalmoscope with a 30-degree field of view centered on the anatomic fovea, with 100% (conventional) laser power and total sensitivity was freely adjusted by the technician to optimize image illumination. To amplify the signal of the final images, a mean image was calculated from 10 acquired images. Figure 1 shows the timeline of clinical events during the follow-up (12 months). Table 1 reported morphological and functional features detected at each time of follow-up.

At the time of presentation, best-corrected visual acuity was 0.0 logMAR (20/20 Snellen). The patient was emmetropic and no significant refractive defects were found in either eye. OCT scan performed at the first outpatient clinic visit showed a small size idiopathic full-thickness macular hole (< 200 microns) with partial posterior vitreous detachment and a firm adherence of posterior cortical vitreous to the edges of the full-thickness macular hole associated with an apparent detached hyaloid outside of the foveal and parafoveal area (Figure 2A). The patient did not attend the scheduled surgical appointment for pars plana vitrectomy, due to a long period of isolation for SARS-COV-2 infection and for a prolonged viral RNA detection after resolution of symptoms. He returned for follow-up two months later. The previous reported full-thickness macular hole spontaneously closed with a reduction of metamorphopsia. OCT scans revealed the appearance of a lamellar macular hole, a subfoveal neurosensory retinal detachment and inner retinal cyst with intact ellipsoid zone

line and external limiting membrane line (Figure 2B OCT image). The OCT-angiography did not detect pathological changes in the perfusion signal in the superficial capillary plexus; the foveal avascular zone area was of 0.15 mm<sup>2</sup> and roundish in appearance. The microperimetry showed a stable fixation and three central points of slightly reduced retinal sensitivity. The short wave-length fundus autofluorescence underlined two hyper-autofluorescence spots with different intensity: the intensity of superior hyper-autofluorescence spot (Figure 2B autofluorescence image: black arrow) was weaker than the inferior one (Figure 2B autofluorescence image: white arrow). Short wave-length fundus autofluorescence/microperimetry integrated assessment highlighted three foveal points of the retinal sensitivity color map microperimetry closer to the hyper-autofluorescence spots: superior, nasal, and temporal. The superior and temporal ones correspond to normo-autofluorescence areas, but they were closest to the superior hyper- autofluorescence spot (Figure 2B autofluorescence image: black arrow), the nasal one fully corresponded to the inferior hyper- autofluorescence spot (Figure 2B autofluorescence image: white arrow). Measured retinal sensitivity was 23, 23, 27 dB of respectively the superior, temporal, and nasal points.

Three months after presentation, the patient did not report any relevant visual disturbance, OCT detected a closure of the previous lamellar macular hole with a residual inner retinal cyst, persistent sub-foveal neurosensory retinal detachment with the occurrence of an interruption of the ellipsoid zone line while the external limiting membrane line was intact (Figure 2C OCT image). The foveal avascular zone area increased to 0.17 mm<sup>2</sup> turning into a more elliptical shape with a greatest vertical diameter. The hyper-autofluorescence points did not show any changes of signal intensity (Figure 2C autofluorescence image: black and white



arrows). The superior retinal sensitivity point remained stable (23 dB), the temporal one improved from 23 to 27 dB, the nasal one worsened from 27 to 21 dB.

Four months after initial visit, the patient complained of worsening metamorphopsia, and OCT detected a recurrent full-thickness macular hole (Figure 2D OCT image). The foveal avascular zone area increased to 0.21 mm<sup>2</sup> keeping an elliptical shape. The superior hyper-autofluorescence spot disappeared, the intensity of the inferior one increased (Figure 2D autofluorescence image: white arrow). The superior retinal sensitivity point remained stable, the temporal one worsened from 27 to 25 dB, the nasal one worsened from 21 to 19 dB.

Eight months later, a spontaneous closure of the hole occurred with near complete resolution of metamorphopsia. The OCT detected a very narrow sub foveal ellipsoid zone line defect and an intact external limiting membrane line, outer nuclear layer reflectivity was completely normal (Figure 2E OCT image). The foveal avascular zone area reduced from 0.21 to 0.17 mm<sup>2</sup> gaining a normal rounding shape and a complete restoration of normo-autofluorescence was detected in the foveal area (Figure 2E autofluorescence image). Concerning the retinal sensitivity points: the superior point improved from 23 to 27 dB, the temporal one improved from 25 to 27 dB, the nasal one partially improved, without reaching normal retinal sensitivity, from 19 to 22 dB.

No other relevant changes were detected during monthly visits over a span of one year, including best corrected visual acuity. The posterior cortical vitreous appeared adherent to the macula without changes during follow-up. The consent to publish medical history, clinical data and images of the instrumental examinations was obtained from the patient.

## DISCUSSION

In this case report, a spontaneous full-thickness macular hole closure with a transitory lamellar macular hole formation was observed. Its recurrence over time and a subsequent spontaneous reclosure, without further tomographic foveal changes up to 12 months, were described. Although cases of spontaneous closure have been reported, no reports involving spontaneous recurrence and reclosure are currently found in the literature. For stage 2 or greater full-thickness macular hole, surgical intervention is recommended differently from lamellar macular hole which can also be observed over time and whose surgical indication is debated. Spontaneous closure of an idiopathic full-thickness macular hole is a rare event that may be observed when surgery is delayed. Various factors affecting spontaneous closure of macular hole have been identified: the reduction of tractional forces after posterior vitreous detachment, the spontaneous proliferation of glial tissue, the formation of an epiretinal membrane, whose contraction could provide the closure of the hole. Early stages of full-thickness macular hole development have been largely described, however, less it is known about the single steps occurring during spontaneous closure; one may hypothesize that it runs through similar steps backwards. Microperimetry, OCT and OCT-angiography allow for the detection of morphological and functional changes. OCT and short wave-length fundus autofluorescence images give qualitative and morphological information requiring a subjective interpretation, while OCT-angiography and microperimetry give quantitative measures. The high intensity and blue light beam used by short wave-length fundus autofluorescence imaging may cause patient discomfort and potential retinal toxicity through retinal pigment epithelium damage. Nevertheless, there are no definitive data about adverse effects. Short wave-length fundus autofluorescence/microperimetry integrated assessment put together the information between them, measuring retinal sensitivity in the foveal hyper-autofluorescence spots and correlating retinal sensitivity, autofluorescence and OCT changes

between themselves. All the changes highlighted by the multi-modal exams performed were analysed and a new and more complete interpretation of the natural evolution of this case report was given. At presentation, OCT imaging revealed a small size idiopathic full-thickness macular hole without posterior vitreous detachment. Many reports demonstrated that mostly small size and early stage idiopathic full-thickness macular holes may undergo closure after spontaneous vitreous separation.<sup>3,6,10</sup> In the present case report, the idiopathic full-thickness macular hole had a small size but posterior cortical hyaloid remained firmly adherent to the macular surface over the entire follow-up. The first observation of spontaneous closure of the hole was characterized by a partial recovery of inner retinal layers with a residual lamellar macular hole and discontinuity of external retinal layers with a consistent sub foveal neurosensory retinal detachment (Figure 2B). At month three, the inner portion appeared securely closed, the external retina discontinued more in the ellipsoid zone and sub foveal neurosensory retinal detachment became smaller (Figure 2C). Inner and external segments of closing macular hole appeared to proceed independently. When transient full-thickness macular hole recurred, at month four, inner retinal segments discontinued with disappearance of cyst and the external retinal dehiscence became the narrowest with flat edges of the full-thickness macular hole (Figure 2D). In the last observation, the hole reclosed with a normal foveal profile, a fully restored reflectivity of the inner layers and the smallest gap in the ellipsoid zone line (Figure 2E). No glial reaction or epiretinal proliferation was observed at the end of follow-up. Other authors reported in their series a residual small defect of photoreceptors layers whose size was directly related to age of patients<sup>3,10</sup>; the current case report confirmed that an ellipsoid zone line defect may be the result of a spontaneously closed idiopathic full-thickness macular hole when observed in a healthy adult patient.

Full-thickness macular hole recurrence and its spontaneous reclosure correspond respectively to an increase and a reduction of the foveal avascular zone. However, the monitoring of foveal avascular zone highlighted an increase of its area before recurrent full-thickness macular hole occurred and when it recurred, foveal avascular zone increased more and reached its highest value.

Two hyper-autofluorescence points had been detected after the first full-thickness macular hole closure. While the superior one disappeared over time, the inferior one increased its intensity when the full-thickness macular hole recurred due to failure of masking effect of inner foveal pigments, thus confirming that it was in a region directly involved by the defect. Hyper-autofluorescence resolution after spontaneous idiopathic full-thickness macular hole closure was like those described by Milani and associates.<sup>6</sup> Short wave-length fundus autofluorescence/microperimetry integrated assessment allowed for the measurement and monitoring of retinal sensitivity in those hyper-autofluorescence spots. The changes in retinal sensitivity were directly related to the integrity of retinal layers, allowing to quantify the loss of retinal sensitivity attributable to the individual layers, 6 dB of reduction of retinal sensitivity due to the interruption of the ellipsoid zone line with full-thickness macular hole closed (Figure 2C), 2 dB of reduction due to the reopening of the full-thickness macular hole therefore to the loss of continuity of the external limiting membrane line and of the other retinal layers (Figure 2D), 3 dB of improvement due to the restoration of the inner retinal layers and of the external limiting membrane line but with discontinuity of the ellipsoid zone (Figure 2E). The trend in retinal sensitivity changes confirms that inner retinal layers may contribute to visual performance with respect to the recognized role of photoreceptors in vitreoretinal surface disorders; as recent evidence suggested.<sup>9</sup>

It is plausible that the development of full-thickness macular hole leads to a reduction of the retinal sensitivity and an enlargement of the foveal avascular zone, but the monitoring of this patient over 12 months shows that these changes began before the hole appeared on OCT scans, so they can be predictive of its formation. The approach with an integrated multi-modal-imaging system, that correlates morphological and morphometric parameters, may allow for the identification of new biomarkers useful in the diagnosis and prognostic evaluation. Multimodal analysis allows for improved interpretation of morphological changes detected by the single instrumental examinations. Visual function may not be sufficient to give information about the course of the vitreoretinal disorders although it is considered the gold standard for the examination of visual performances because of its availability and reproducibility. Best-corrected visual acuity is likely to provide only a restricted representation of foveal and perifoveal status. In fact, the best-corrected visual acuity did not change during the follow-up, this may be related to the small size of the full-thickness macular hole that does not lead to a reduction in visual acuity as with the transitory lamellar macular hole. Microperimetry has proven to be a fundamental exam to assess extensively macular function. The theories presented here would be strengthened if baseline microperimetry, short wave-length fundus autofluorescence and OCT-angiography data have been registered. Baseline examinations were not performed, the patient was indeed booked for surgery following presentation. Further in-depth imaging was performed following the spontaneous closure of the hole.

## **CONCLUSIONS**

The monitoring of full-thickness macular hole with multiple imaging modalities such as OCT, OCT-angiography, short wave-length fundus autofluorescence, microperimetry and their overlaying elaboration can add new biomarkers with diagnostic and prognostic value.

## REFERENCES

1. Gass JD. Reappraisal of Biomicroscopic Classification of Stages of Development of a Macular Hole. *Am J Ophthalmol* 1995;119:752-9.
2. Liang X, Liu W. Characteristics and Risk Factors for Spontaneous Closure of Idiopathic Full-Thickness Macular Hole. *J Ophthalmol* 2019; 2019:4793764.
3. Privat E, Tadayoni R, Gaucher D, et al. Residual Defect in the Foveal Photoreceptor Layer Detected by Optical Coherence Tomography in Eyes with Spontaneously Closed Macular Holes. *Am J Ophthalmol* 2007;143:814-9.
4. Ishida M, Takeuchi S, Okisaka S. Optical Coherence Tomography Images of Idiopathic Macular Holes with Spontaneous Closure. *Retina* 2004;24:625-8.
5. Inoue M, Arakawa A, Yamane S, et al. Long-term Outcome of Macular Microstructure Assessed by Optical Coherence Tomography in Eyes with Spontaneous Resolution of Macular Hole. *Am J Ophthalmol* 2012;153:687-91.
6. Milani P, Seidenari P, Carmassi L, Bottoni F. Spontaneous Resolution of a Full Thickness Idiopathic Macular Hole: Fundus Autofluorescence and OCT Imaging. *Graefes Arch Clin Exp Ophthalmol* 2007;245:1229-31.
7. Frisina R, Pilotto E, Midena E. Lamellar Macular Hole: State of the Art. *Ophthalmic Res* 2019;61:73-82.
8. García Fernández M, Castro Navarro J. Spontaneous Closure of Stage IV Idiopathic Full-Thickness Macular Hole and Late Reopening as a Lamellar Macular Hole: A Case Report. *J Med Case Rep* 2012;6:2-5.
9. Frisina R, Tozzi L, Gius I, et al. Novel Approaches to the Assessment and Treatment of Lamellar Macular Hole. *Acta Ophthalmol* 2022;100:e1287-97.
10. Zambarakji HJ, Schlottmann P, Tanner V, et al. Macular Microholes: Pathogenesis and Natural History. *Br J Ophthalmol* 2005;89:189-93.

**Table 1.** Summary of the morphological and functional features detected during follow-up by means of optical coherence tomography (OCT), angiography-OCT (A-OCT), short wave-length fundus autofluorescence (SwFAF), and microperimetry (MP).

Timing of follow-up	OCT foveal morphology	ELM line integrity	EZ line integrity	Subfoveal neurosensory retinal detachment	FAZ area	BCVA	swFAF intensity of Superior point (S)– Inferior point (I)	RS in tested foveal points: Superior– Temporal –Nasal
Months	Descriptive features (FTMH, LMH, pseudocysts)	intact/disrupted	intact/disrupted	present/absent	mm <sup>2</sup>	logMAR	NF/low-HF/medium-HF/high-HF	dB
Baseline	FTMH	disrupted	disrupted	absent	na	0.0	na	na
2	closed FTMH with residual LMH	intact	intact	present	0.15	0.0	S–low-HF I–medium-HF	23–23–27
3	closed FTMH with residual inner pseudocysts	disrupted	intact	present	0.17	0.0	S–low-HF I–medium-HF	23–27–21
4	FTMH recurrence	disrupted	disrupted	absent	0.21	0.0	S–NF I–high-HF	23–25–19
8–12	closed FTMH with inner layers integrity	disrupted	intact	absent	0.17	0.0	S–NF I–NF	27–27–22

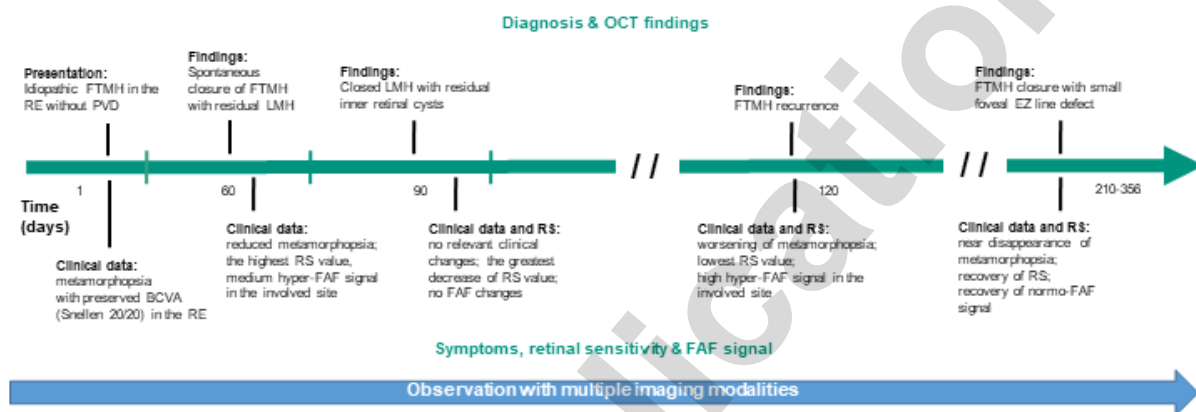
ELM = external limiting membrane; EZ = ellipsoid zone; FAZ = foveal avascular zone; BCVA = best-corrected visual acuity; swFAF = short wavelength fundus autofluorescence; RS = retinal sensitivity; FTMH = full-thickness macular hole; LMH = lamellar macular hole; NF = normo-FAF; HF = hyper-FAF; na = not available

## FIGURE LEGENDS

**Figure 1.** Timeline of clinical events across the 1-year observation of an idiopathic full-thickness macular hole spontaneous closure in a 46-year-old white male. FTMH = full-thickness macular hole. RE = right eye; PVD = posterior vitreous detachment; LMH = lamellar macula hole; EZ = ellipsoid zone; BCVA = best-corrected visual acuity; RS = retinal sensitivity; FAF = fundus autofluorescence.

**Figure 2.** Spontaneous closure of idiopathic full-thickness macular hole (iFTMH), a long-term follow-up (12 months). Multiple imaging and functional modalities including optical coherence tomography (OCT), angiography-OCT (A-OCT), short wave-length fundus autofluorescence (sw-FAF), microperimetry (MP) and their overlaying elaboration. **(A)** Baseline OCT linear scan shows the iFTMH. White and black arrowheads show respectively external limiting membrane (ELM) and ellipsoid zone (EZ). **(B)** Two months later, appearance of an early lamellar macular hole (LMH) (arrow), inner retinal cyst (star), subfoveal neurosensory retinal detachment (dashed line) with both EZ and ELM intact. Foveal avascular zone (FAZ) area was  $0.15 \text{ mm}^2$ . Sw-FAF: two hyper-fundus autofluorescence (FAF) points, the superior (black arrow) weaker than inferior one (white arrow). MP: central fixation (red ring) and retinal sensitivity (RS) of foveal test points. Overlapped sw-FAF/MP: superior and temporal tested points (respectively S and T) are closest to the superior hyper-FAF spot, the nasal one (N) fully corresponded to the inferior hyper-FAF spot. RS of S, T, N was 23, 23, 27 dB. **(C)** Three months later, resolution of LMH with residual cyst and subfoveal neurosensory retinal detachment (stars), EZ interrupted while ELM was intact. FAZ area was  $0.17 \text{ mm}^2$ . Sw-FAF unchanged (black and white arrows). RS of S, T, N was 23, 27, 21 dB. **(D)** Four months later, iFTMH recurrence (dashed line). FAZ area was  $0.21 \text{ mm}^2$ . Superior hyper-FAF spot disappeared, the intensity of inferior one increased (white arrow). RS of S, T, N was 23, 25, 19 dB. **(E)** Eight months later, Over 12 months, iFTMH reclosed with restored reflectivity of inner retinal layers, ELM intact, EZ interrupted (star). FAZ area was  $0.17 \text{ mm}^2$ . Sw-FAF: disappearance of hyper-FAF points. RS of S, T, N was 27, 27, 22 dB.





**Figure 1.** Timeline of clinical events across the 1-year observation of an idiopathic full-thickness macular hole spontaneous closure in a 46-year-old white male. FTMH = full-thickness macular hole; RE = right eye; PVD = posterior vitreous detachment; LMH = lamellar macula hole; EZ = ellipsoid zone; BCVA = best-corrected visual acuity; RS = retinal sensitivity; FAF = fundus autofluorescence

Figure 2

