

strated Wallerian degeneration of corneal nerves.³ To date, histopathology has not been used to study limbal corneal innervation after diode cyclophotocoagulation,⁴ and a similar degeneration may occur as with cycloablation.

Because this side effect was not anticipated, corneal sensation of our patients was not assessed before cycloablation. Both patients had predisposing conditions for decreased corneal innervation to which the cycloablation probably was additive. Unfortunately, many eyes considered for cycloablation have such predisposing characteristics. Clinicians should be aware of possible neurotrophic corneal defects after diode laser cycloablation and realize the likelihood of needing tarsorrhaphy and the potential for devastating visual loss should a neurotrophic keratitis occur. Assessment of corneal sensation before diode laser cycloablation may be helpful in determining which patients are at most risk for subsequent neurotrophic keratitis.

REFERENCES

1. Bietti G. Recent experimental, clinical and therapeutic research on the problems of intraocular pressure and glaucoma. *Am J Ophthalmol* 1972;73:475-500.
2. Kosoko O, Gaasterland DE, Pollack IP, Enger CL. Long-term outcome of initial ciliary ablation with contact diode transscleral cyclophotocoagulation for severe glaucoma. *Ophthalmology* 1996;103:1294-1302.
3. Wener R, Pinkerton RMH, Robertson DM. Cryosurgical induced changes in corneal nerves. *Can J Ophthalmol* 1973;8:548-555.
4. Hennis HL, Assia E, Steward WC, Legler UFC, Apple DJ. Transscleral cyclophotocoagulation using a semiconductor diode laser in cadaver eyes. *Ophthalmic Surg* 1991;22:274-278.

Choroidal Calcification in Bartter Syndrome

Giorgio Marchini, MD, Roberto Tosi, MD, Barbara Parolini, MD, Giovanna Castagna, MD, and Marco Zarbin, MD, PhD

Accepted for publication April 1, 1998.

Department of Ophthalmology, University of Verona, Verona, Italy (G.M., R.T., B.P., G.C.) and Department of Ophthalmology, University of Medicine and Dentistry of New Jersey, Newark, New Jersey (M.Z.).

Inquiries to Giorgio Marchini, MD, Clinica Oculistica dell'Università di Verona, Ospedale di Borgo Trento, I-37126 Verona, Italy; fax: -39-45-8072025; e-mail: barbaggio@hotmail.com

PURPOSE: Bartter syndrome is characterized by hyperplasia of the renal juxtaglomerular apparatus, hyperaldosteronism, and hypokalemic alkalosis. We report a case of Bartter syndrome associated with normal serum calcium levels and posterior choroidal calcification.

METHODS: Case report. A 59-year-old man with bilateral cataract and Bartter syndrome underwent a complete ophthalmic examination, including standardized echography before and after cataract surgery.

RESULTS: Before cataract surgery, echography identified small, hyperreflective, multifocal, bilateral choroidal lesions with posterior shadowing. After surgery, these lesions appeared as yellow-white, barely elevated plaques with smooth edges and were diagnosed as choroidal calcification.

CONCLUSIONS: Choroidal calcification may occur in patients with Bartter syndrome. This condition should be added to the differential diagnosis of posterior segment calcification. (*Am J Ophthalmol* 1998;126:727-729. © 1998 by Elsevier Science Inc. All rights reserved.)

BARTTER SYNDROME¹ IS ASSOCIATED WITH HYPERplasia and hypertrophy of the renal juxtaglomerular apparatus, hypokalemic metabolic alkalosis, increased prostaglandin synthesis, and secondary hyperaldosteronism. The absence of hypertension in the presence of high plasma renin levels and insensitivity to the effect of angiotensin on blood pressure are characteristic. Abnormalities such as hyperuricemia, hypomagnesemia, gout arthropathy, and chondrocalcinosis have been described.^{2,3} Clinical presentations include a severe childhood form of the disease, associated with growth retardation, and a largely asymptomatic adult form.⁴ We report a case of Bartter syndrome with hypomagnesemia, chondrocalcinosis, normocalcemia, and bilateral multifocal choroidal calcification.

A 59-year-old man was referred for treatment of bilateral cataracts. His medical history was notable for acute arthritis of the left elbow and for acute recurrent polyarthritis, particularly severe in both knees and in both metatarsophalangeal joints, bilateral meniscectomy, and right knee synovectomy for

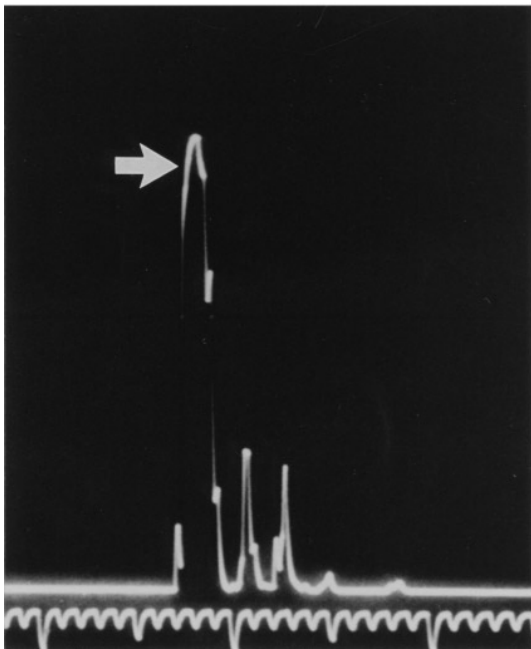
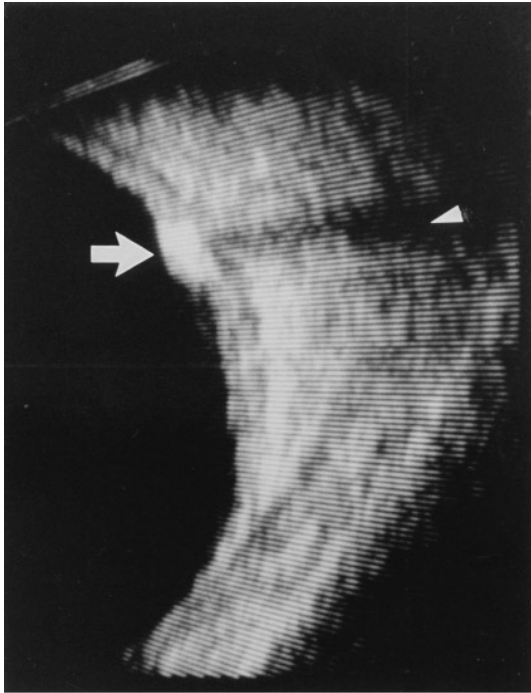


FIGURE 1. (Top) Examination with standardized B-scan echography shows that the fundus lesions (arrow) are characterized by high reflectivity and posterior shadowing (arrowhead), typical signs of choroidal calcification. (Bottom) A-scan echography of the same lesion (arrow). A-scan image at T-20 dB.

joint deformation. Pathologic study confirmed the presence of severe meniscus calcification and chronic synovitis with chondrocalcinosis.

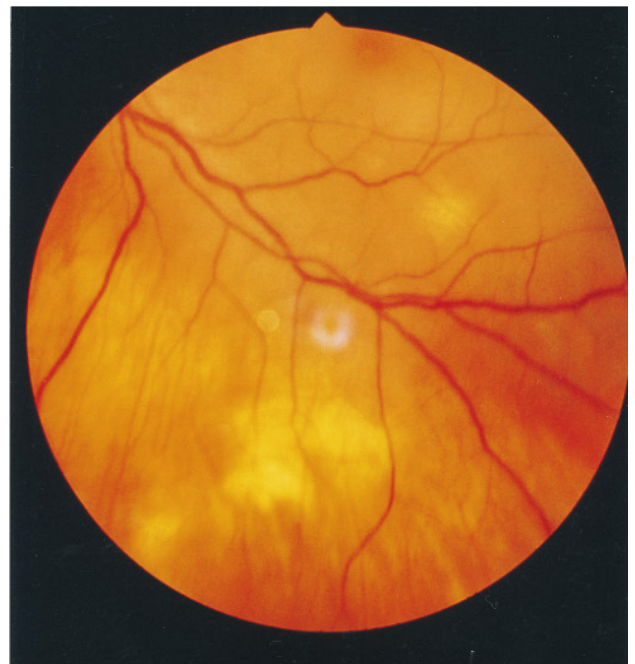
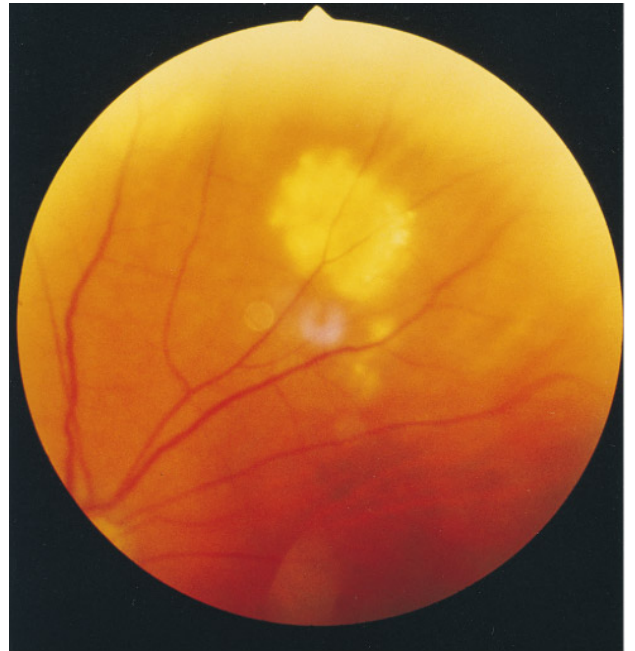
FIGURE 2. (Top) Fundus photograph of the left eye. A round, yellow plaque with regular edges less than 2 disk diameters in the superonasal quadrant is shown. (Bottom) Fundus photograph of the left eye. Plaques in the inferotemporal quadrant.

An adult low-penetrance form of Bartter syndrome was diagnosed in the patient around 1981, based on the findings of hypokalemic alkalosis (serum potassium: 2.3 to 2.8 mmol/l; normal: 3.7 to

5.0 mmol/l), hyperuricemia (8.4 mg/100 ml; normal: 3 to 7 mg/100 ml), normal blood pressure, and the absence of a hypertensive response to angiotensin II infusion. In 1988, hypomagnesemia was found (0.5 mmol/l; normal: 0.7 to 1.1) and persisted even though the patient received oral supplementation. Despite this finding, the patient's serum calcium and phosphate levels have remained normal.

After gradual loss of vision, the patient was referred to our clinic for cataract extraction in his left eye. Best-corrected visual acuity was RE, 20/30 and LE, 20/400. The slit-lamp examination was normal except for bilateral nuclear sclerotic cataracts. Intraocular pressure was 16 mm Hg in both eyes. Fundus examination of the right eye disclosed a normal-appearing optic nerve, major retinal vessels, and macula. Several round, barely elevated, white plaques with smooth edges, less than 2 disk diameters in size, were irregularly distributed between the posterior pole and the equator. There was no view of the left fundus because of cataract. Echographic examination of the left eye with standardized A- and B-scan technique disclosed small (maximum thickness: 2.5 mm), solid, multifocal choroidal lesions exhibiting high reflectivity and posterior shadowing (Figure 1), similar in both eyes and characteristic of choroidal calcification. Both clinically and echographically, the lens did not show evidence of calcification. The patient underwent cataract surgery in his left eye with posterior chamber intraocular lens implantation. At 2 months follow-up, visual acuity was LE, 20/25. Indirect ophthalmoscopic findings of the left eye after cataract surgery were similar to those of the right eye, as described above (Figure 2).

To our knowledge, the association between Bartter syndrome and bilateral choroidal calcification has not been described previously. Because head computed tomography and magnetic resonance imaging were not done, we do not know if other areas of calcification were present in the central nervous system. Some authors emphasize that hypomagnesemia, often present in Bartter syndrome, may be important in the pathogenesis of chondrocalcinosis by reducing the activity of the pyrophosphatase and by promoting pyrophosphate crystallization.⁵ Similar mechanisms might contribute to the development of the ocular

posterior segment calcification. The solid nature of the lesions, the high echographic impedance, and the posterior shadowing are all typical of choroidal calcification. Calcification may be idiopathic or present in a number of different posterior segment conditions, for example, tumors of the retina and of the choroid, abnormalities associated with hypercalcemia, posttrauma, postinflammatory and degenerative diseases, and optic nerve head drusen. The solid, bilateral, multifocal, choroidal lesions that we report in association with Bartter syndrome should be included in the differential diagnosis of posterior segment calcification.

REFERENCES

1. Bartter FC, Pronove P, Gill JR Jr, MacCardle RC. Hyperplasia of the juxtaglomerular complex with hyperaldosteronism and hypokalemic alkalosis. *Am J Med* 1962;31:811-828.
2. de Heide LJ, Birkenhager JC. Bartter's syndrome, hypomagnesaemia and chondrocalcinosis. *Neth J Med* 1991;39:148-152.
3. Jones AC, Chuck AJ, Arie EA, Green DT, Doherty M. Diseases associated with calcium pyrophosphate deposition disease. *Semin Arthritis Rheum* 1992;22:188-202.
4. Simopoulos AP, Bartter FC. Growth characteristics and factors influencing growth in Bartter syndrome. *J Pediatr* 1972;81:56-65.
5. Goulon M, Raphael JC, De Rohan P. Syndrome de Bartter et chondrocalcinose. Une association non fortuite. *Nouv Presse Med* 1980;9:1291-1295.

Human Immunodeficiency Virus-Associated Vision Loss: Electroretinogram Attenuation

Sean P. Donahue, MD, PhD

PURPOSE: To report a 35-year-old man with human immunodeficiency virus (HIV) and bilateral progressive decrease in vision thought to be caused by HIV optic neuropathy but associated with a severe attenuation of the electroretinogram.

Accepted for publication April 2, 1998.

From the Departments of Ophthalmology & Visual Sciences, Pediatrics and Neurology, Vanderbilt University School of Medicine, Nashville, Tennessee. This work supported in part by a grant from Research to Prevent Blindness, Inc, New York, New York.

Inquiries to Sean P. Donahue, MD, PhD, 1215 21st Ave S, Vanderbilt Medical Center East, 8th Fl, Nashville, TN 37232-8808; fax: (615) 936-1540.