

# Role of OCT in the diagnosis and follow up of diabetic macular edema

Giacomo Panozzo, Elena Gusson, Barbara Parolini and Andrea Mercanti

TECLO SRL, Vitreoretinal Service, Verona, Italy

## Abstract

The aim is to present, along with a brief literature review, the results of OCT scan in eyes with diabetic macular edema (DME), as well as examples of the utility of OCT for different therapeutic approaches. One-hundred and thirty-six eyes with diabetic retinopathy were analyzed with OCT to explore the different patterns of DME. Some eyes with DME were studied with OCT pre and postoperatively to determine the efficacy of photocoagulation and vitrectomy to restore a normal macular profile. Sixty-eight eyes with a central foveal thickness of 200  $\mu$  or more were considered “edematous”. Three different patterns of DME were recognized and analyzed: macular thickening, cystoid macular edema and shallow retinal detachment. The change in macular profile and internal retinal structure after laser or surgical treatment are well visible with OCT. OCT contributes in understanding the anatomy of DME and the intraretinal damage and seems to be the technique of choice for the follow-up of macular edema. We think that this tool should always be used in monitoring the effect of therapies in future studies.

**Keywords:** Diabetic macular edema; OCT; macular thickening

Since the publication of the Early Treatment Diabetic Retinopathy Study (ETDRS)<sup>1</sup>, Diabetic Macular Edema (DME) has been defined as diffuse or focal macular thickening, with or without hard exudates that can be complicated by the formation of intraretinal cystoid spaces. This thickening is judged clinically relevant when involving or threatening the macula (thickening or hard exudates plus adjacent thickening at less than 500 microns from the center of foveal avascular zone) and called Clinically Significant Macular Edema (CSME).

It has been stated that visual function in patients with DME is inversely correlated to central retinal thickening and

not to capillary leakage, and that the restoration of normal macular thickness may be followed by partial recovery of visual function.<sup>2</sup> Derived from these observations, DME and particularly CSME are diagnosed in the ETDRS recommendations at biomicroscopy by direct observation of the thickened retina or by comparison of the suspected area with an adjacent area of “normal” thickness. Intraretinal leakage is not necessary to confirm the presence of DME, and fluorescein angiography (FA) is useful only as a guide for focal or grid laser treatment of thickened areas.

While massive or extensive edema is easily seen at the slit lamp, a subtle CSME is difficult to be appreciated, as well as small intraretinal cystoid spaces or subtle epiretinal changes. Moreover, the evaluation of thickness change after laser or surgical treatment is left to clinical and subjective impression.

With high-resolution cross sectional scanning of the entire macular area, OCT can be fundamental in the diagnosis and follow up of DME, giving not only an objective measurement of macular thickness with a resolution of 10 microns, but also an image of intraretinal structure and epiretinal tractions.<sup>3</sup>

Commercially available since 1995, OCT has been used by the vast majority of Authors for epidemiological or pathophysiological studies on DME and for monitoring the results of a variety of laser or surgical treatments.<sup>4-10</sup> As for many other macular pathologies, the use of OCT added new insights on patterns of DME and their impact on visual function and on the potential benefit of new therapies.

In this article, along with a brief literature review, the authors present the results of OCT scans in 68 diabetic eyes

---

The authors have no financial interests in equipment mentioned in the present article.

with DME, as well as examples of the utility of OCT in different therapeutic approaches.

### Normal foveal thickness

Hee *et al.* analyzed 73 normal eyes from 41 healthy volunteers (mean age, 38 years, range 23–79 years).<sup>5</sup> The average thickness (mean  $\pm$  SD) in an area of 500 microns in diameter centered in the fovea, was  $174 \pm 18\mu\text{m}$  and never exceeded  $216\mu\text{m}$ , while central foveal thickness was  $152 \pm 21\mu\text{m}$ . The data has been confirmed by different authors.<sup>11</sup>

In a small series of 15 normal eyes we confirmed a reproducible normal foveal thickness within the above ranges (Fig. 1).

### Central foveal thickness in DME

We analyzed 136 eyes with diabetic retinopathy with OCT and in accordance with other authors we considered “edematous” eyes with central foveal thickness of 200 microns or more.<sup>5,11</sup> A total number of 68 eyes in our group were over this measure and have been considered in this series.

### Patterns of DME

Otani and coworkers, in a series of 59 eyes, described three configurations of DME: sponge-like retinal swelling, cystoid macular edema and serous retinal detachment.<sup>11</sup>

We hereafter describe these patterns and add some personal observations from our case series of 68 eyes with DME (Table 1).

1. **Type 1: Sponge-like Retinal Swelling** (Fig. 2): increased retinal thickness with reduced intraretinal reflectivity. The

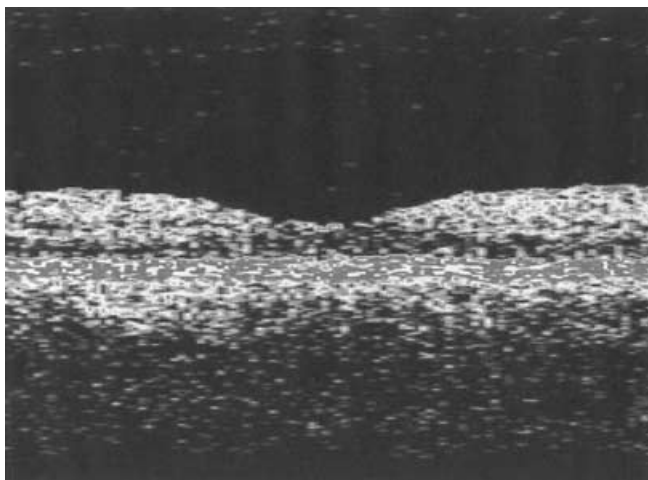


Figure 1. Normal macula. Central foveal thickness 155 microns.

retina resembles a sponge with the internal layers maintaining a normal reflectivity, and areas of low reflectivity located in the outer layers. This is the most common configuration of DME, present in Otani's series isolated or in combination with other configurations in 52 eyes (88%). In our case series this pattern was present in 5 eyes (7%) and in 59 cases (86.7%) combined with other forms.

2. **Type 2: Cystoid Macular Edema** (Fig. 3a,b,c): intraretinal cystoid spaces in the macular area. This form of edema, isolated or in combination with other patterns, was present in 47% of cases in the Otani's series. In our case series the presence of isolated intraretinal cysts without swelling was very rare (2 cases, 2.9%), but very common in combination with sponge-like swelling (56 eyes, 82.4%). The number and configuration of cystoid spaces is variable, and we divided the isolated presence of one or two small cysts (*Type 2a*: 19 cases in our series, 27.9%)

*Table 1.* Mean macular thickness of our case series of 68 eyes. Thickness at foveal center and at 1–3–6 millimeters from foveal center, based on the ETDRS-based retinal maps furnished by OCT. The isolated patterns of cystoid edema and serous macular detachment are not included.

| Group                          | Eyes | Fovea | 1 mm  | 3 mm  | 6 mm  |
|--------------------------------|------|-------|-------|-------|-------|
| Total group                    | 68   | 387.5 | 390.8 | 381.8 | 326.2 |
| Type 1 CSME                    | 5    | 221.2 | 248.2 | 308.8 | 300.2 |
| Type 1 and 2 CSME (mixed form) | 56   | 405.5 | 406.2 | 391.3 | 331.9 |
| Laser-treated eyes*            | 22   | 405.9 | 412.4 | 417.6 | 360.5 |
| PPV-treated eyes*              | 22   | 389.9 | 388.9 | 371.5 | 313.8 |

PPV = pars plana vitrectomy.

\* the difference in thickness between these values is not statistically significant.

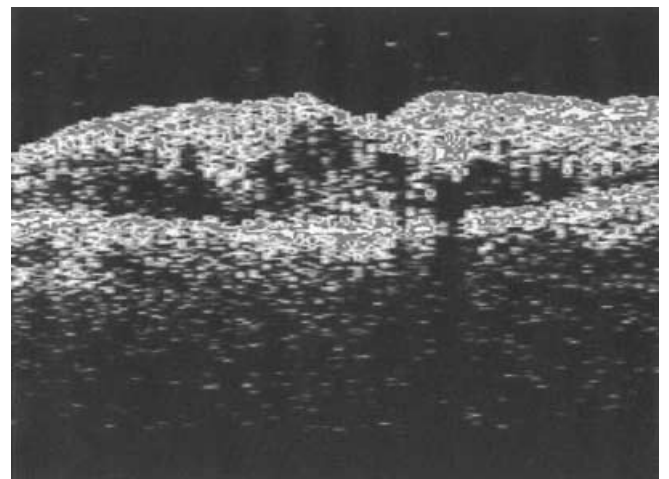
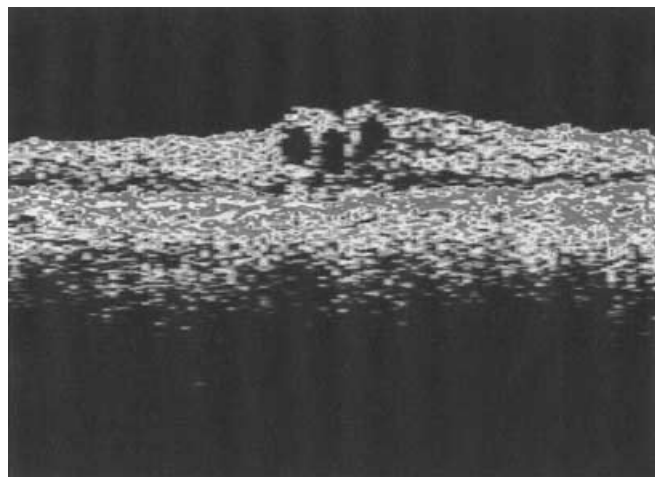
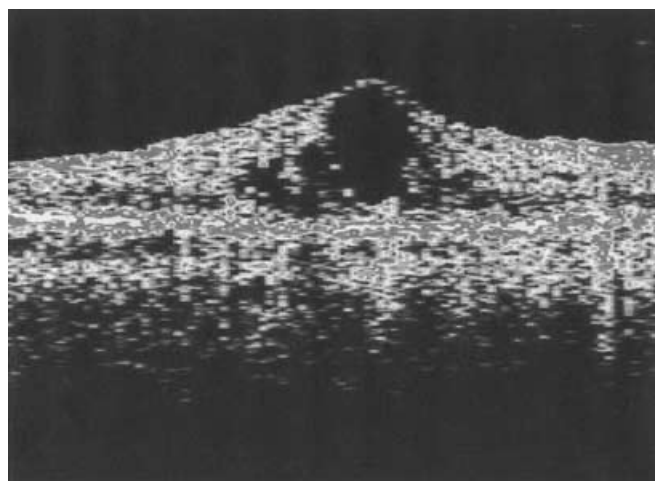


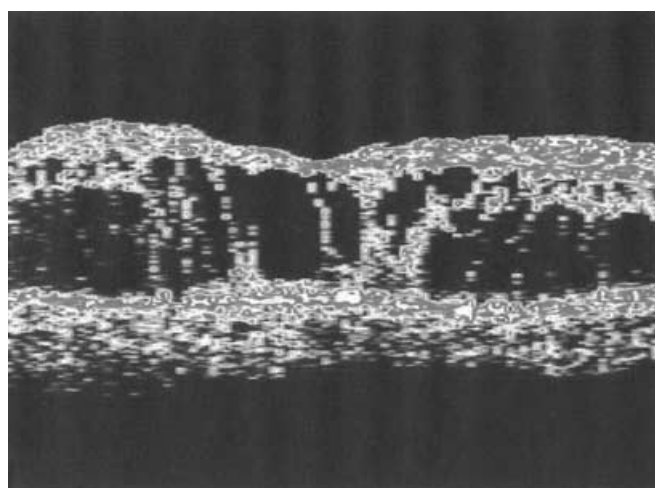
Figure 2. CSME Type 1: Sponge-like retinal swelling. Central thickness 435 microns.



A



B

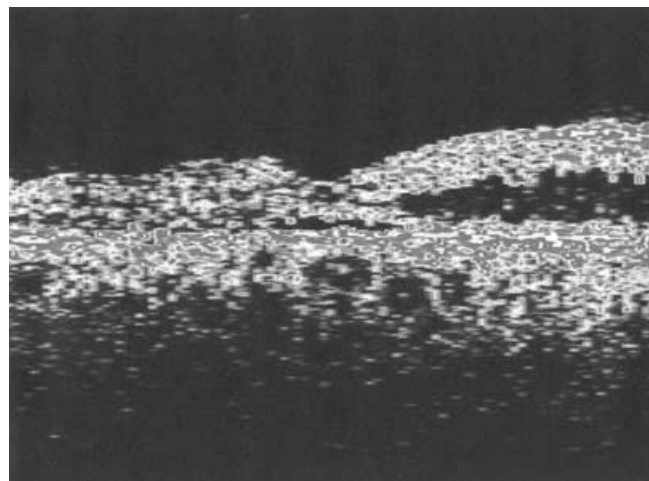


C

*Figure 3.* a. CSME Type 2a: small intraretinal cysts in the inner plexiform layer. The normal macular profile is still visible but the central foveal thickness is 325 microns.

b. CSME Type 2b: Petaloid pattern of intraretinal cysts. Central foveal thickness 485 microns.

c. CSME Type 2c: Chronic cystoid edema. Major intraretinal damage with cysts fused in large cavities resembling retinoschisis. Central foveal thickness 405  $\mu\text{m}$ .



*Figure 4.* CSME with mixed pattern Type 3 and 2c: subfoveal shallow serous retinal detachment and perifoveal diffuse retinal swelling.

from the typical petaloid pattern (*Type 2b*: 21 eyes, 30.9%) and finally the coalescence of cysts in large cavities (*Type 2c*: 14 cases, 20.6%).

3. **Type 3: Serous Retinal Detachment** (Fig. 4). Although rare, a subfoveal shallow retinal detachment can be seen in some cases of DME (15% of cases in the Otani series, 10 eyes, 14.7% in our series).

In Table 1 we report the mean macular thickness at the foveal center, at one, three and six millimeters from the foveal center in our case series.

**Hard exudates.** When present, hard exudates can be detected by OCT as spots of high reflectivity with corresponding deep shadows, and can be located not only into the neurosensory retina, but also in the subretinal space in the presence of a reabsorbing serous detachment.<sup>12</sup>

In summary, the high resolution of OCT allows in vivo confirmation of the histopathology of DME and the observation of the progressive retinal damage.

Intraretinal fluid from leaking capillaries accumulates in the interneural virtual space of the outer plexiform layer of Henle. According to Otani *et al.*, under the resolution power of OCT, the sponge-like swelling probably represents a recently formed edema with intracytoplasmic swelling of Müller cells or small extracellular deposits.<sup>11</sup> In chronic stages, enlarged cystic spaces are easily seen in the outer retina, first as isolated small empty areas (Fig. 3a) but evolving with time to a petaloid pattern (Fig. 3b).

The inner retina is initially preserved and maintains a high reflectivity, while in chronic cases the cysts fuse together to form large cavities. At that point the retinal structure is entirely involved and damaged, with progressive necrosis of Müller and neural cells. The macular area is totally hyporeflexive (Fig. 3c). In the most severe stages the retina is totally substituted by glial tissue with cysts but normal thickness.



### Epiretinal tractions

In some cases, DME can be associated with changes of the internal retinal surface determined by diffuse or focal traction from the thickened and taut posterior hyaloid, the internal limiting membrane or from epiretinal membranes.<sup>13,14</sup> The presence of tangential or antero-posterior forces can be clearly demonstrated by OCT and indicates the most appropriate treatment.

The significance of internal tractions in the formation or maintenance of DME is still unclear, but there is increasing evidence that these forces may play a role in the determination of edema.<sup>13-20</sup>

In Figure 5 a foveal traction by an incomplete posterior vitreous detachment is probably the cause of DME.

### Topography of DME

OCT enables not only the measurement of foveal thickness but also the depiction of a complete retinal thickness map of the macular area.<sup>3-5</sup> This option is particularly useful in the diagnosis of CSME with retinal thickening threatening but not involving the fovea and also in the follow-up of laser or surgical treatment.

The macular map can be obtained with a standardized method by six radial optical tomograms of six millimeters centered on the fovea and measuring a total number of 600 points along these lines.

The retinal thickness data are displayed in two complementary ways (Fig. 6). For quantitative interpretation the macula is divided in nine ETDRS-type regions and for each zone an average retinal thickness is given. For rapid and easy evaluation and for comparison of two or more examinations, a false-color topographic map is also provided.

In Table 2 we report the mean thickness values of our series of 68 eyes, separately for different patterns and for eyes treated with laser photocoagulation and with vitrectomy.

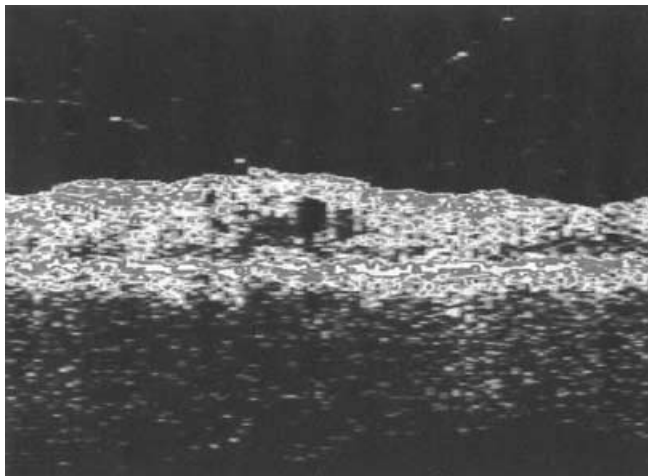


Figure 5. CSME Type 2 associated with vitreofoveal traction. Posterior hyaloid has an arcuate configuration and is firmly attached to the fovea.

### OCT versus biomicroscopy in the detection of CSME

The sensitivity of biomicroscopy and OCT in the diagnosis of macular thickening and CSME has been compared.<sup>4</sup> The two methods are equally effective in the detection of advanced cases with definite thickening or wide cystic changes.

However, shallow changes in retinal thickening of less than 100 microns are invisible at slit lamp and easily observed at OCT.<sup>4</sup>

OCT therefore seems to be more sensitive in the early diagnosis of DME and in the detection of small changes in

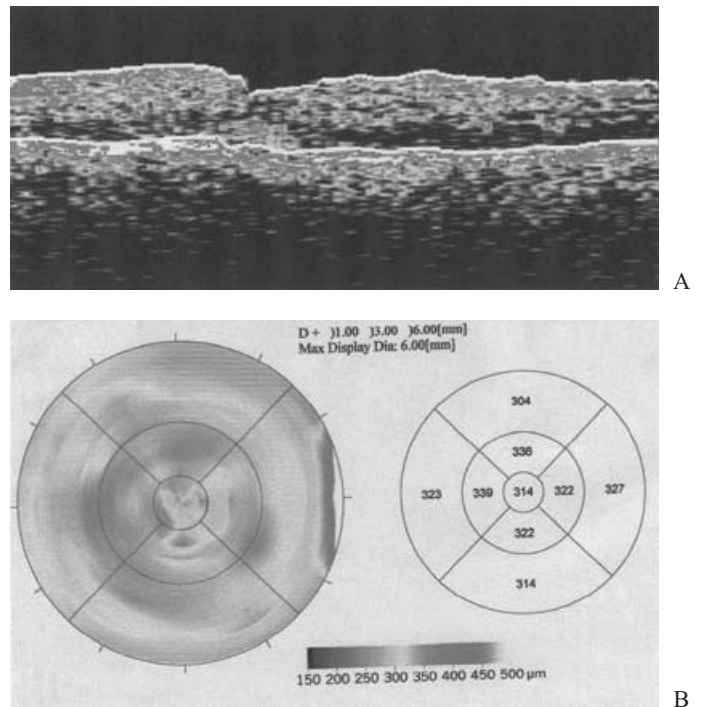
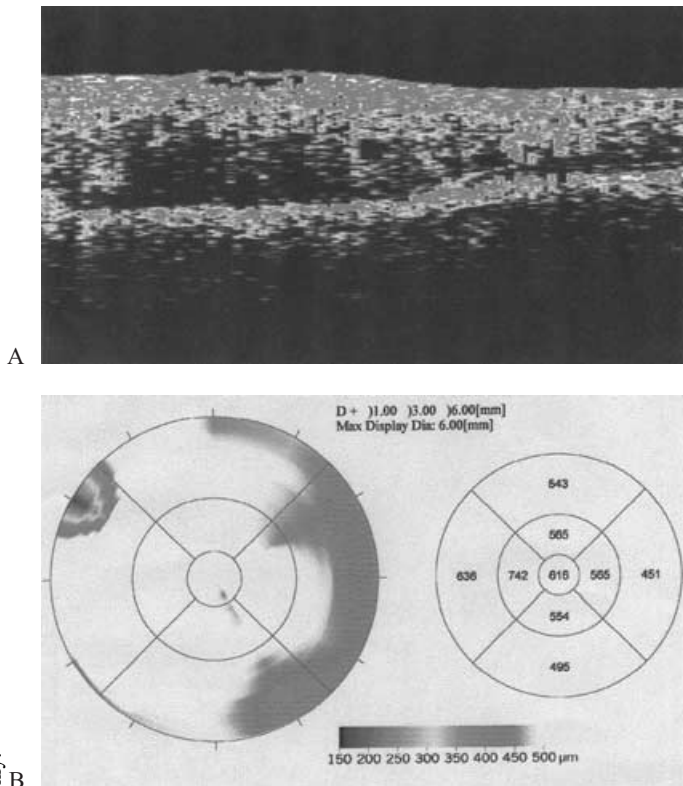


Figure 6. Measurement of macular thickness in a case of CSME Type 1.

- a. Tomography. Each focal thickness measurement between the two white lines can be easily taken.
- b. Retinal color and quantitative map of macular area (diameter of the circumference: 6 mm).

Table 2. Pattern of CSME in our case series of 68 eyes.

| Pattern                             | Eyes | %    |
|-------------------------------------|------|------|
| Type 1 isolated                     | 5    | 7    |
| Type 1 combined with other patterns | 59   | 86.7 |
| Type 2 isolated                     | 2    | 2.9  |
| Type 2 combined with other patterns | 56   | 82.4 |
| Type 2a (combined)                  | 19   | 27.9 |
| Type 2b (combined)                  | 21   | 30.9 |
| Type 2c (combined)                  | 14   | 20.6 |
| Type 3 (combined)                   | 10   | 14.7 |



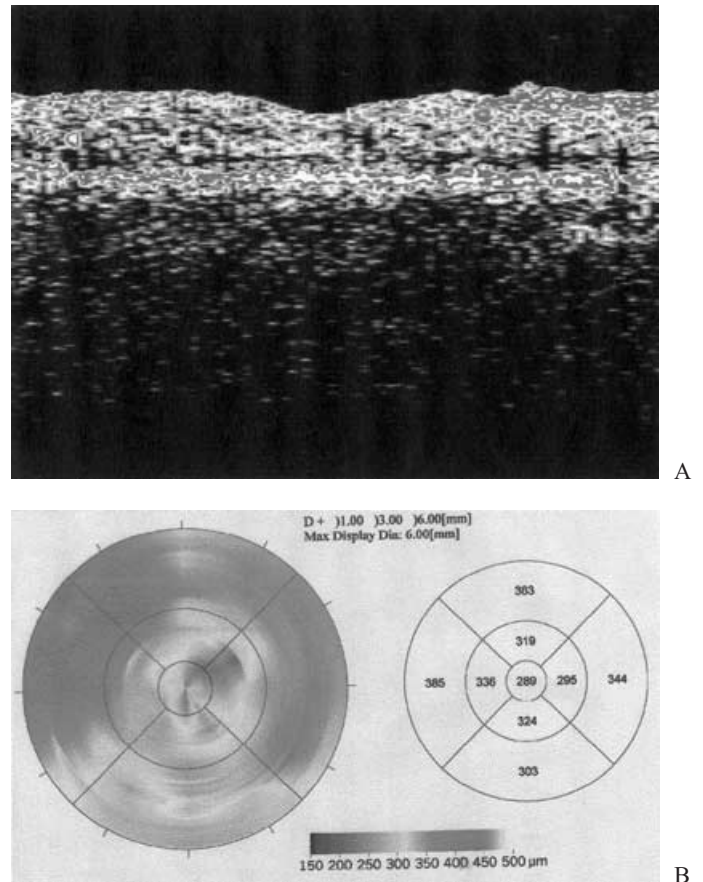
**Figure 7. Case 1 pre-op.**

- Pre-operative OCT of sponge-like retinal swelling (Type 1) associated with epiretinal tractions from incomplete posterior vitreous detachment.
- Pre-operative retinal map: the prevalence of white color indicates a diffuse thickening over 550 microns. Visual acuity 20/400.

retinal thickness after treatment. Moreover, the presence of shallow retinal detachments or fine epiretinal membranes or a partially detached posterior hyaloid are only observed by OCT.<sup>13,14</sup>

### Relationship between foveal thickness and visual acuity

OCT may detect subtle changes in retinal thickness with a resolution of 10–20 microns, therefore enabling the establishment of a good correlation between foveal thickening and visual function. This inverse relationship between increasing central foveal thickness and visual acuity, upon which the ETDRS classification of DME stands, has been confirmed by plotting measurement of retinal thickness with OCT versus visual acuity of the same patients.<sup>4,11</sup> It has been observed that over 350 microns of foveal thickness visual acuity is generally reduced below 20/400. Although in randomly selected diabetic patients it is usually difficult to correlate macular thickness with visual acuity due to the confounding presence of many factors that can influence visual function (hard exudates, central capillary drop out cystic retinal changes, neural damage etc) we generally observed the same linear correla-



**Figure 8. Case 1 pre-op.**

OCT two months after pars plana vitrectomy and gas tamponade. Visual acuity 20/100.

- Impressive resolution of macular edema and recovery of normal macular profile.
- Retinal map showing a minor residual macular thickening.

tion in our group: on 45 eyes with CSME and central foveal thickness over 350 microns, visual acuity was always 20/160 or less, while the 23 eyes with swelling less than 300 microns had visual acuity of 20/125 or more.

### Treatment of DME

The goal of DME treatment is threefold and aims to improve anatomy, physiology and therefore function of the macular area by preventing the progressive deposition of intraretinal fluid and proteinaceous debris and releasing the traction forces exerted onto the fovea.

Different treatment options are available at the moment. While focal or grid laser treatment still remains the gold standard, there is increasing evidence that vitrectomy with detachment of the posterior hyaloid, with or without peeling of the internal limiting membrane and epiretinal membranes may lead to partial recovery of visual function.<sup>13–23</sup>

The evaluation of the effect of each treatment has to be judged both by the improvement in visual acuity and by the

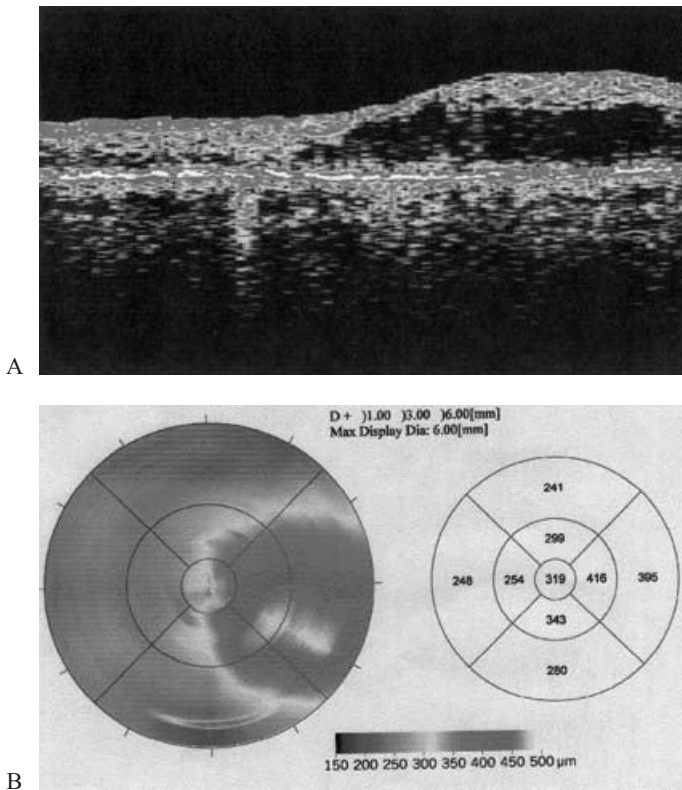


Figure 9. **Case 2 pre-laser tr.** Visual acuity 20/100.

- a. Six mm scan demonstrating a Type 1 pattern of CSME, with temporal swelling involving the fovea.
- b. Retinal map clearly depicts the asymmetric thickening of the macular area.

observation of the structural changes induced. OCT gives an objective and reproducible measurement of retinal thickness and intraretinal structure and has been used to monitor the results of treatment in recent literature.<sup>24</sup>

The following three cases, treated at our Retinal Service, highlight the importance of OCT in deciding the best treatment option for DME as well as the follow-up.

**Case 1**

Male, 55 years of age, with non-insulin dependent diabetes for 15 years. He had already received panphotocoagulation OU and vitrectomy in the RE for proliferative retinopathy and vitreous hemorrhage.

Visual acuity in the right eye was progressively declining from 20/50 to 20/400 for the presence of CSME Type 1 and 2 associated with diffuse epiretinal traction from incomplete posterior vitreous detachment clearly confirmed at OCT (Fig. 7 a,b).

We decided to perform a second vitrectomy with posterior hyaloid peeling and C3F8 gas tamponade in January 2002. In two months visual acuity improved to 20/100, with resolution of tractions, recovery of normal macular profile and major reduction in macular thickening (Fig. 8 a,b).

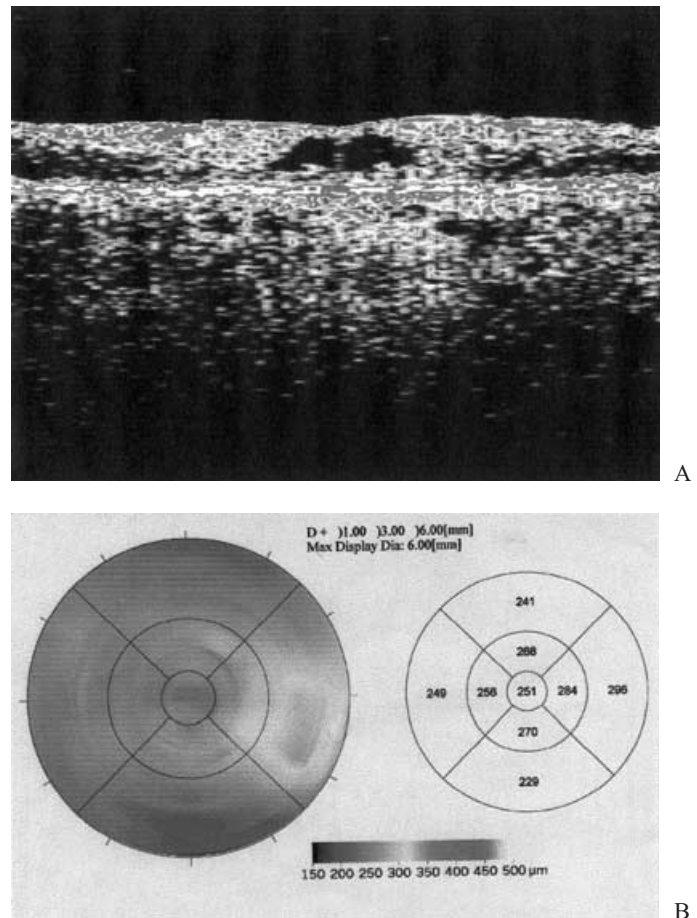


Figure 10. **Case 2 pre-laser tr.** OCT images five months after subthreshold grid diode laser treatment of the CSME. Visual acuity improved to 20/40.

- a. The vast majority of the edema has reabsorbed. Two small central intraretinal cysts (Type 2 CSME) are still visible.
- b. The retinal map evidences a lowering of temporal swelling of more than 100 microns.

**Case 2**

Female, 50 years old, with proliferative diabetic retinopathy already panphotocoagulated in both eyes.

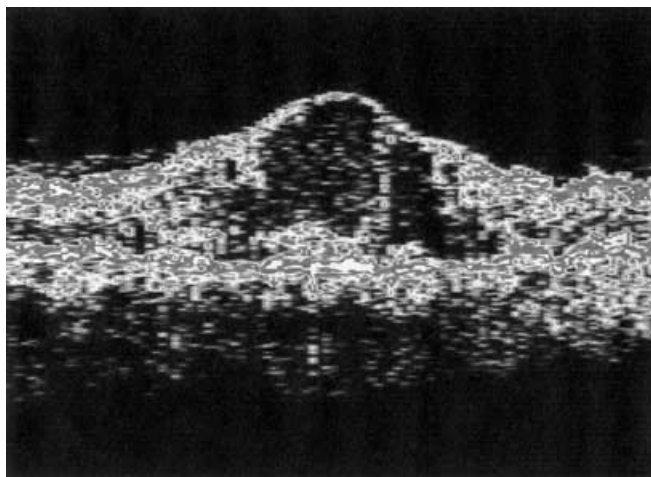
In April 2001 visual acuity in the left eye was 20/100 for the presence of macular thickening confined in the temporal quadrant and involving the fovea. At OCT a retinal thickening was present. OCT shows a Type 1 pattern of CSME (Fig. 9 a,b).

She received a sub-threshold diode grid laser treatment in the area of macular thickening in June 2001. At follow-up, retinal thickening progressively lowered and the visual acuity improved in five months to 20/40 (Fig. 10 a,b).

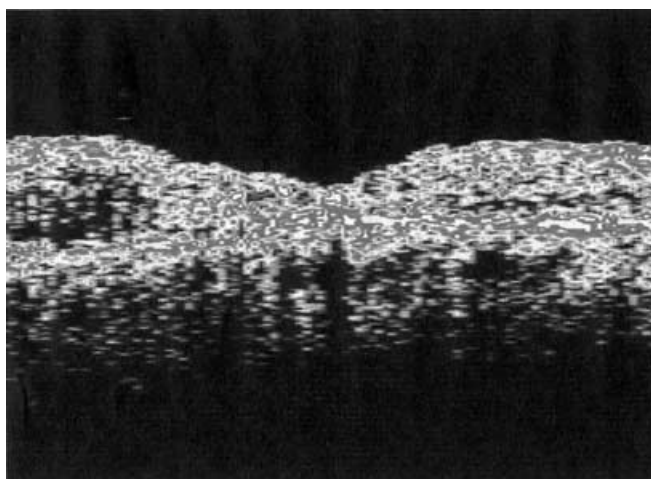
**Case 3**

A 60-year-old female with chronic diabetic cystoid macular edema received multiple laser treatments for proliferative retinopathy. Previous grid argon treatments in the





A



B

Figure 11. Case 3.

- a. Pre-operative OCT, Type 1 and 2 macular edema, with central foveal thickness of 670 micron and visual acuity of 20/400.
- b. OCT two months after vitrectomy and gas tamponade. Complete resolution of edema and recovery of normal macular profile. Visual acuity is still low (20/200) for the presence of central hard exudates (high subfoveal reflectivity) and capillary drop out.

macular area failed to improve vision, dropped down to 20/400 OU.

OCT performed in October 2001 showed in the RE a severe and diffuse macular thickening with central foveal swelling of 670 (Fig. 11a). In December 2001 she underwent vitrectomy with C3F8 tamponade in the RE. Four months post-operatively OCT confirmed a dramatic resolution of the macular edema (Fig. 11b). Although post-operatively visual acuity had a minor change from 20/400 to 20/200 for the presence of capillary atrophy and central hard exudates, the patient showed major improvement in visual field and contrast sensitivity.

## Conclusion

OCT can provide a major contribution to the understanding of the anatomy of DME and the intraretinal damage.

The ability of available therapies in reversing macular edema has to be measured objectively, and only separately correlated to visual function, usually affected by various components. At the moment OCT seems to be the technique of choice for the follow-up of macular edema. We think that this tool should always be used in monitoring the effect of therapies in future studies.

## References

1. Early Treatment Diabetic Retinopathy Study Research Group. ETDRS report number 7. Early Treatment Diabetic Retinopathy Study design and baseline patient characteristics. *Ophthalmology*. 1991;98:741–756.
2. Nussenblatt RB, Kaufman SC, Palestine AG *et al.* Macular thickening and visual acuity. Measurement in patients with cystoid macular edema. *Ophthalmology*. 1987;94:1134–1139.
3. Hee MR, Izatt JA, Swanson EA *et al.* Optical Coherence Tomography of the Human Retina. *Arch Ophthalmol*. 1995;113:325–332.
4. Hee MR, Puliafito CA, Wong C *et al.* Quantitative assessment of macular edema with optical coherence Tomography. *Arch Ophthalmol*. 1995;113:1019–1029.
5. Hee MR, Puliafito CA, Duker JS *et al.* Topography of diabetic macular edema with optical coherence Tomography. *Ophthalmology*. 1998;105:360–370.
6. Puliafito CA, Hee MR, Lin CP *et al.* Imaging of macular diseases with optical coherence tomography. *Ophthalmology*. 1995;102:217–229.
7. Hee MR, Puliafito CA, Wong C *et al.* Optical coherence Tomography of macular holes. *Ophthalmology*. 1995;102:748–756.
8. Hee MR, Bauman CR, Puliafito CA *et al.* Optical coherence Tomography of age-related macular degeneration and choroidal neovascularization. *Ophthalmology*. 1996;103:1260–1270.
9. Wilkins JR, Puliafito CA, Hee MR *et al.* Characterization of epiretinal membranes using optical coherence Tomography. *Ophthalmology*. 1996;103:2142–2151.
10. Schuman JS, Pedut-Kloizman T, Hertzmark E *et al.* Reproducibility of nerve fiber layer thickness measurements using optical coherence Tomography. *Ophthalmology*. 1996;103:1889–1898.
11. Otani T, Kishi S, Maruyama Y. Patterns of diabetic macular edema with optical coherence Tomography. *Am J Ophthalmol*. 1999;127:688–693.
12. Otani T, Kishi S. Tomographic findings of foveal hard exudates in diabetic macular edema. *Am J Ophthalmol*. 2001;131:50–54.
13. Kaiser PK, Riemann CD, Sears JE, Lewis H. Macular traction detachment and diabetic macular edema associated with posterior hyaloidal traction. *Am J Ophthalmol*. 2001;131:44–49.
14. Yamamoto T, Akabane N, Takeuchi S. Vitrectomy for diabetic macular edema: the role of posterior vitreous detach-

- ment and epimacular membrane. *Am J Ophthalmol.* 2001;132:369–377.
15. Lewis H, Abrams GW, Blumenkranz MS, Campo RV. Vitrectomy for diabetic macular traction and edema associated with posterior hyaloidal traction. *Ophthalmology.* 1992;99(5):753–759.
  16. Harbour JW, Smiddy WE, Flynn HW Jr, Rubsamen PE. Vitrectomy for diabetic macular edema associated with a thickened and taut posterior hyaloid membrane. *Am J Ophthalmol.* 1996;121(4):405–413.
  17. Nasrallah FP, Van de Velde F, Jalkh AE, Trempe CL, McMeel JW, Schepens CL. Importance of the vitreous in young diabetics with macular edema. *Ophthalmology.* 1989;96(10):1511–1517.
  18. Hikichi T, Fujio N, Akiba J *et al.* Association between the short-term natural history of diabetic macular edema and the vitreomacular relationship in type II diabetes mellitus. *Ophthalmology.* 1997;104(3):473–478.
  19. Van Efferente G, Guot-Argenton C, Guiberteau B, Hany I, Lacotte JL. Macular edema caused by contraction of the posterior hyaloid in diabetic retinopathy. Surgical treatment of a series of 22 cases. *J Fr Ophthalmol.* 1993;16:602–610.
  20. Ikeda T, Sato K, Katano T, Hyashi Y. Attached posterior hyaloid membrane and the pathogenesis of honeycombed cystoid macular edema in patients with diabetes. *Am J Ophthalmol.* 1999;127(4):478–479.
  21. Lewis H. The role of vitrectomy in the treatment of diabetic macular edema. *Am J Ophthalmol.* 2001;131:123–125.
  22. Gandorfer A, Messmer EM, Ulbig MW, Kampik A. Resolution of diabetic macular edema after surgical removal of the posterior hyaloid and the inner limiting membrane. *Retina.* 2000;20(2):126–133.
  23. Early Treatment Diabetic Retinopathy Study Research Group. Treatment techniques and clinical guidelines for photocoagulation for diabetic macular edema; early treatment diabetic retinopathy study report number 2. *Ophthalmology.* 1987;94:761–774.
  24. Otani T, Kishi S. Tomographic assessment of vitreous surgery for diabetic macular edema. *Am J Ophthalmol.* 2000;129(4):487–494.