

Diode laser, vitrectomy and intravitreal triamcinolone. A comparative study for the treatment of diffuse non tractional diabetic macular edema

Parolini B., Panozzo G., Gusson E., Pinackatt S., Bertoldo G., Rottini S. and Pignatto S.

Teclio Vitreo-Retinal Service, Verona

Abstract

Purpose. To determine the effectiveness and safety of diode laser, pars plana vitrectomy (PPV) with gas tamponade, and intravitreal triamcinolone (IVT) as possible treatments for diffuse diabetic macular edema (dDME).

To determine whether the new macular edema Classification previously proposed by some of the authors may help as a guide in the choice of treatment.

Methods. A retrospective, comparative study of 169 eyes with dDME that underwent treatment. The eyes were divided into 3 groups: in the PPV Group, 59 eyes received PPV with gas tamponade; in the DIODE Group, 53 eyes received a laser grid; in the IVT Group, 57 eyes received an intravitreal injection of 4 mg of triamcinolone acetonide. The follow up ranged from 6 to 24 months. The eyes were classified according to the new DME Classification based on OCT.

Main outcomes. Change in foveal thickness as determined by Optical Coherence Tomography (OCT); change in visual acuity; intra and postoperative complications.

Results. Mean visual acuity (VA) improved at 3 months with every treatment. At one year only eyes which underwent PPV still had a better VA than the pre-op value, while eyes which underwent IVT and laser treatment showed regression. PPV show the greater percentage of eyes which gain 3 or more lines of VA at one year (17%).

Mean foveal thickness improved at 3 months with every treatment. Only the eyes into the PPV Group showed relatively low foveal thickness at one year.

Better final VA and foveal thickness were obtained if preop VA is ≥ 0.3 and if earlier stages of DME were treated according to the new DME Classification.

PPV was the treatment which offered the most stable results with at one year or longer. Similar results were observed into the PPV Groups as a whole and into a subgroup of eyes with preoperative PVD.

No complications were encountered with laser diode treatment. Long term complications into the IVT Group were elevated IOP (8%), retinal detachment (3.5%) and posterior cataract (15%).

Long term complications into the PPV Group were retinal detachment (3.4%) and cataract (90%).

Conclusions. Diode laser, PPV with gas tamponade and IVT are effective alternative treatments to decrease foveal thickness and improve visual acuity in eyes with DME. However while the results of PPV are stable in the long term follow-up, diode laser and IVT do not offer stable results. Complications may be severe with PPV and IVT. It is necessary to carefully select cases which would benefit from these types of treatments. The authors think that the OCT Classification may serve as a guide for the choice of treatment.

Introduction

The major cause of visual loss in patients with diabetic retinopathy is macular edema (ME).¹ The incidence of diabetic macular edema (DME) increases with duration of

Correspondence: Giacomo Panozzo, MD, Teclio Vitreo-Retinal Services, Via Del Perlar 2, Verona 37135, Italy. E-mail: g.panozzo@iol.it

diabetes. It is reported to be 14% to 25% depending on the type of the diabetes.¹

Various treatments have been tried to resolve DME.

Medical treatments such as aldose reductase inhibitors have been attempted but with unsuccessful results.² Hyperbaric therapy seems to have a beneficial but temporary effect,³ and is not practical at present.

Laser photocoagulation is currently the mainstay of treatment for DME by grid macular photocoagulation. The Early Treatment Diabetic Retinopathy Study (ETDRS).⁴ demonstrated that photocoagulation of DME reduces the risk of moderate visual loss by 50%. Only 3% of eyes improved three lines or more of visual acuity (VA) with laser.⁴ The visual prognosis after photocoagulation to treat diffuse macular edema was worse than when it was used to treat focal macular edema.⁵

Argon-green is the most commonly used wavelength, although comparable results have also been reported with yellow and other visible wavelengths.⁶ More recently, sub-threshold diode laser (810nm) has been tried.⁷ This wavelength is primarily absorbed by the deeper layers of the retina and choroid, sparing the inner retinal layers.

The clinical course of DME has been evaluated after treatment with intravitreal triamcinolone acetonide injection (IVT) first in 2001.⁸ Then various authors reported the results of the procedure, but different techniques were reported with a consequent difficulty in comparing the results. Furthermore, only short term follow-ups are usually available.⁹

In the last decade, the role of pars plana vitrectomy (PPV) in the treatment of DME has been investigated with increasing interest.

The first attempt was made in 1992 by Lewis¹⁰ who performed PPV with removal of an attached taut and thickened posterior hyaloid on 10 patients. In eight of them, after more than one year, DME had resolved and VA improved.

After that, many studies have reported on the results of surgery for treatment for DME in the presence or absence of posterior vitreous detachment (PVD) and in the presence or absence of epiretinal membranes.¹¹⁻²⁰

While it is accepted that vitrectomy may be the best treatment for E in the presence of vitreo-retinal traction and that laser is the best treatment for focal macular edema, the treatment of diffuse non-tractional macular edema is not clearly defined.

From this large variety of treatment options and different techniques for each treatment, the following issues have emerged as critical:

Is there a unique treatment for diffuse DME (dDME)?

Are there different indications for photocoagulation, intravitreal steroids and for PPV in the treatment of diffuse DME?

Is there a best timing for treatment?

In the last decade, the use of optical coherence tomography (OCT. Humphrey model 2000, Humphrey Instruments, San

Leandro, California, USA) added new insights on patterns of DME and their impact on visual function and on the potential benefit of new therapies.

With the high-resolution cross sectional scanning of the entire macular area, OCT can be fundamental in the diagnosis and follow up of DME, giving not only an objective measurement of the macular thickness with a resolution of 10 microns,²¹ but also an image of intraretinal structure and epiretinal tractions.

Commercially available in 1995, OCT has been used by the vast majority of Authors for epidemiological or pathophysiological studies on DME and for monitoring the results of a variety of laser or surgical treatments.²²⁻²⁸

Might the use of OCT really improve the quality of treatment and the therapeutic results?

In a previous paper (), the authors proposed a new Classification of macular edema with the use of OCT.

The new Classification, indicates that DME has different morphologic patterns.

Therefore the authors added one more question to be answered by the clinical trial:

Could each OCT morphologic pattern of DME benefit more by one of the treatments?

The authors thought that these issues could only be clarified by a clinical trial endeavoring the effort to compare the effectiveness and safety of the three most widely accepted treatment options available at the moment for DME: laser photocoagulation, PPV and IVT.

The results of the clinical trial are presented in the present paper.

To our knowledge this is the first attempt to make a comparative study among the three treatment option selected.

Methods

In the present study, 169 eyes with diffuse non-tractional DME were treated from January 1999 to January 2004.

Each treatment was performed by two of the authors (GP or BP).

The eyes were divided into three treatment groups:

1. **PPV Group** Fifty-nine eyes received a standard complete pars plana vitrectomy (PPV) under local anesthesia, posterior vitreous cortex separation, when attached to the retina, and gas tamponade (C3F8 14%). The presence or absence of PVD was registered during surgery and considered in the analysis of the results.
2. **IVT Group** Fifty-seven eyes received an intravitreal injection of 4mg of triamcinolone acetonide via pars plana in the inferior quadrant with a 25 or 27 G needle and a syringe. Topical anesthesia and a sterile procedure were used for every patient. The procedure was performed into the operating room. Intraocular pressure (IOP) was checked before treatment and then 5, 10 and 30 minutes

after treatment. In none of the eyes a paracentesis was needed to lower the IOP.

3. **DIODE Group** Fifty-three eyes were treated with a diode laser with a sub-threshold grid pattern into the macula. Grid was performed by placing radial rows of 3 to 5 non-visible spots up to 300 micron from the center of the foveal avascular zone. The correct power was obtained by placing a few visible test spots outside the macula and then by gradually lowering the power of the laser to find the “non-visible sub threshold spot”.

In the years 2001 and 2002, DME eyes were randomly assigned to the DIODE Group or to the PPV Group. Between September 2002 and January 2004, DME eyes were treated with IVT.

DME classification

According to the morphologic Classification published by the authors and based on OCT findings, DME is divided into different morphologic subtypes as follows: E1 refers to the simple thickening, E2 to the thickening associated to cystoid changes (E2a mild, E2b intermediate, E2c severe cystoid thickening), E3 to the presence of neuroepithelial detachment associated or not to E1 or E2 (for detailed description of the Classification, see the paper published in this issue).

Only at the end of the study and during the analysis of the data, each eye was classified according to the new DME Classification.

Follow-up

Postoperatively, the eyes in the PPV Group were tested at 3, 6, 12 and 24 months; the eyes in the IVT Group were tested at 1, 3, 6 and 12 months; the eyes in the DIODE Group were tested at 3 and 6 and 12 months.

Eyes in the PPV Group could not receive the 1 month visit due to the presence of internal gas tamponade into the vitreous cavity.

Eyes into the IVT Group did not receive the 24 months visit because the treatment was started more recently.

VA was tested with Snellen charts.

Each eye received OCT scan and a complete ophthalmic evaluation preoperatively and at each postoperative visit.

Main outcomes

The main outcomes of the study were:

- a. the functional result, i.e., the change in VA
- b. the anatomic result, i.e., the change in central retinal thickness as measured by OCT.

In particular the aim of the study was to answer to the following specific questions:

1. Which is the change in the average VA with time into the 3 treatment groups? which is the percentage of eyes

which gain three or more lines of VA in any treatment group?

2. Which is the change in the average foveal thickness with time for the 3 treatment groups?
3. May the pre-op VA influence the results?
4. Is OCT helpful in understanding which type of DME may benefit more and by which treatment? I.e., is the DME morphology an important factor?
5. Is PPV possibly beneficial only when the posterior hyaloid is still attached to the retina?

Results

DIODE group

Gender. Twenty patients were male and 11 were female.

The mean age of the group was 67 years.

DME subtypes. E1: 6 eyes; E2a: 9 eyes; E2b: 22; E2c: 8 eyes; E3: 11 eyes.

PPV group

Gender. Twenty patients were male and 12 patients were female.

The mean age of the group was 68 years.

DME subtypes: E1: 11 eyes; E2a: 7 eyes; E2b: 25 eyes; E2c: 5 eyes; E3: 9 eyes.

IVT group

Gender. Twenty-six patients were male and 11 were female.

The mean age of the group was 65 years.

DME subtypes: E1: 11 eyes; E2a: 7 eyes; E2b: 25 eyes; E2c: 5 eyes; E3: 9 eyes.

Change in visual acuity with treatment

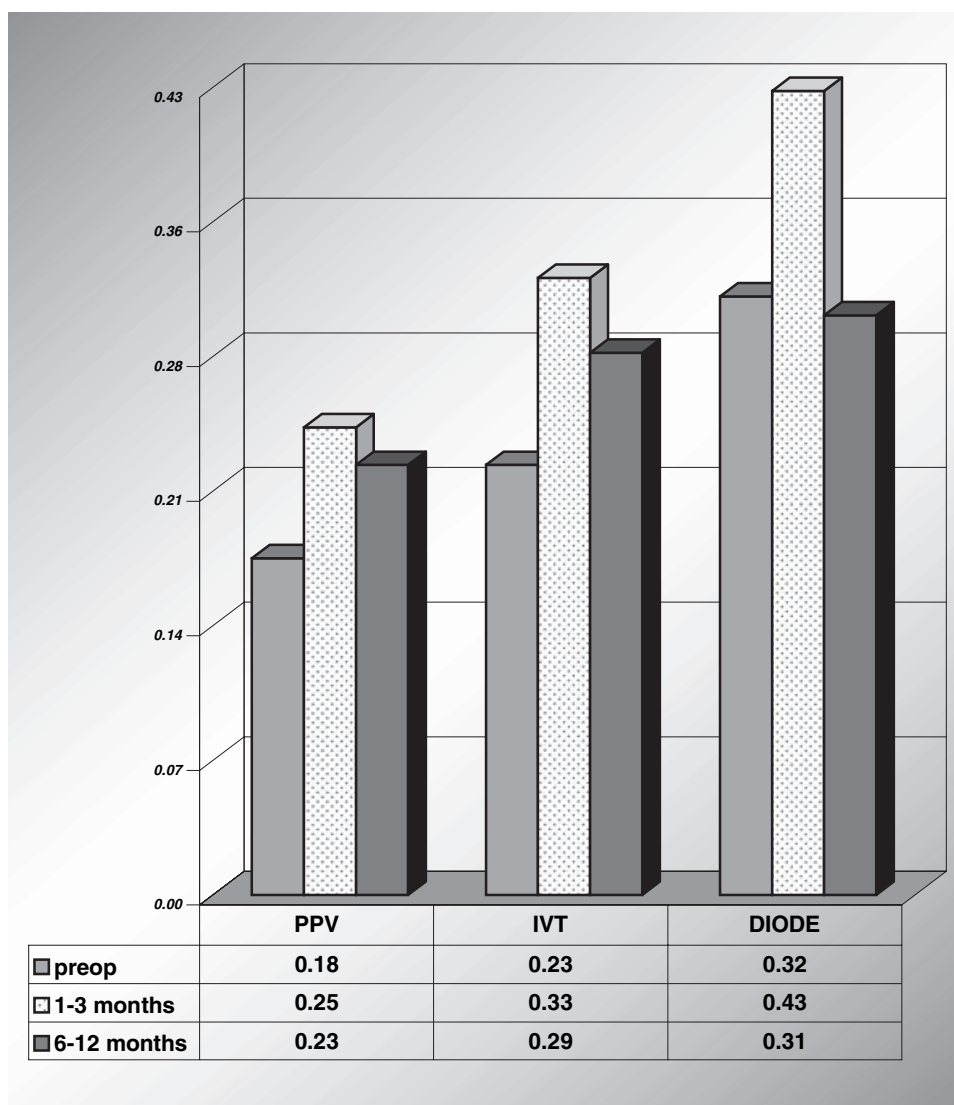
The change in the mean VA with time per each treatment group was analyzed first.

The mean VA into the PPV Group was preoperatively 0.18 and increased to 0.25 at the early follow-up visit (1–3 months). At the late follow-up visit (6–12 months) it was 0.23.

The mean VA into the IVT Group was preoperatively 0.23 and increased to 0.33 at the early follow-up visit (1–3 months) but showed a relapse to 0.24 at the late follow-up visit (6–12 months).

The mean VA into the DIODE Group was preoperatively 0.32 and increased to 0.43 at the early follow-up visit (1–3 months). At the late follow-up visit (6–12 months) it was 0.31.

As shown in graph 1, if the preoperative value is compared with the late value (one year), only the eyes treated with PPV show a slight improvement in VA (from 0.18 to 0.23) while the eyes treated with IVT and with laser show a great improvement in the early stage (1 to 3 months) but a decrease in vision with time (between 6 and 12 months after



Graph 1. Change in the mean VA with time per treatment group.

treatment). The difference in VA between the pre-op value and the 3 m post-op value is statistically significant for PPV ($p = 0.01$), for IVT ($p = 0.001$) and for DIODE ($p = 0.02$). The difference in VA between the pre-op value and the 6–12 m post-op value is not statistically significant for any of the treatment group.

The percentage of eyes which gained 3 lines or more of VA was than analyzed (Graph 2).

At one month only the data of the IVT Group were available because the vitrectomized eyes still were filled with gas and the eyes into the DIODE Group were not analyzed at one month.

After IVT there was a high percentage of eyes which improved early, 24% at one month, but at 6 months (16%) and at one year (9%) the number decreased, while after PPV the number of eyes which improved vision increased with time (11% at 6 months, 17% at one year). The number of eyes with improved vision with laser was similar to PPV

at 6 months (9%) but decreased at one year dramatically (4%).

Overall the effectiveness on visual function was minimal with every treatment for dDME, at least when considering only the average VA of the study group as a whole.

Graph 3 shows how the average VA changes with time, considering all the 169 eyes without differentiating the type of treatment.

Change in foveal thickness with treatment

Graph 4 shows the change of the mean foveal thickness with time per treatment group.

The mean preoperative foveal thickness into the PPV Group was 463μ and decreased to 361μ at the early follow-up visit (1–3 months) and then again to 327μ at the late follow-up visit (6–12 months).

The mean preoperative foveal thickness into the IVT Group was 493 μ and decreased to 275 μ at the early follow-up visit (1–3 months) but showed a relapse to 327 μ at the late follow-up visit (6–12 months).

The mean preoperative foveal thickness into the DIODE Group was 435 μ and decreased to 381 μ at the early follow-up visit (1–3 months) and then again to 226 μ at the late follow-up visit (6–12 months).

The difference in foveal thickness between the pre-op value and the 3 m post-op value was statistically significant

for PPV ($p = 0.01$), for IVT ($p = 0.00001$) and for DIODE ($p = 0.02$). The difference in foveal thickness between the pre-op value and the 6–12 m post-op value was still statistically significant in the PPV Group ($p = 0.0004$) and in the DIODE Group ($p = 0.0008$) but not statistically significant for IVT Group. It must be taken into account however that at one year 20% of the eyes into the DIODE Group were lost because they received different treatment due to worsening of the edema. Therefore the apparently good result in terms of mean foveal thickness at one year in the DIODE Group may be not acceptable.

At final follow-up the average foveal thickness was still out of the normal range ($180 \pm 20\mu$). Graph 5 shows how foveal thickness changed with time, considering all the 169 eyes without differentiating the type of treatment.

The influence of pre-op VA on the results

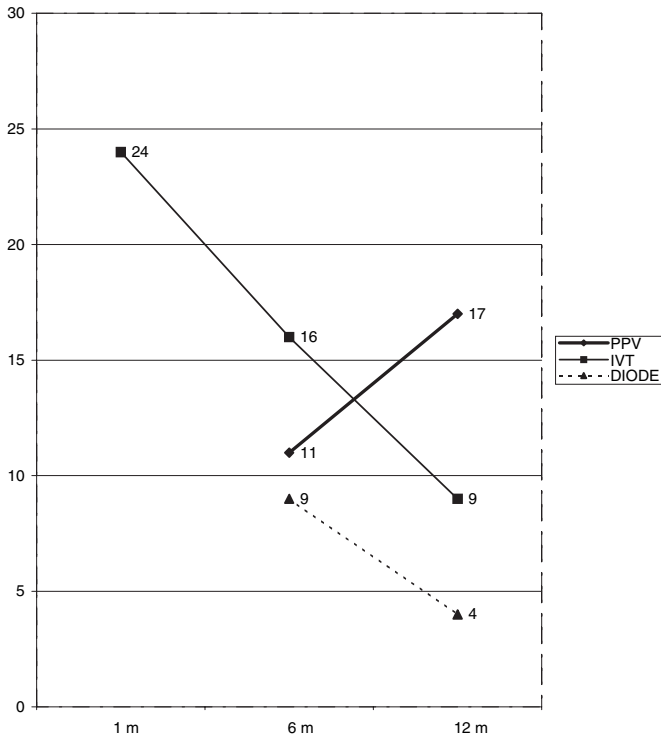
The functional and anatomical results were more favorable when considering a subgroup of eyes with preoperative VA ≥ 0.3 .

In fact the final VA at the late follow-up was higher (graph 6) when compared to the late postoperative value of VA of each treatment Group as a whole (see graph 1).

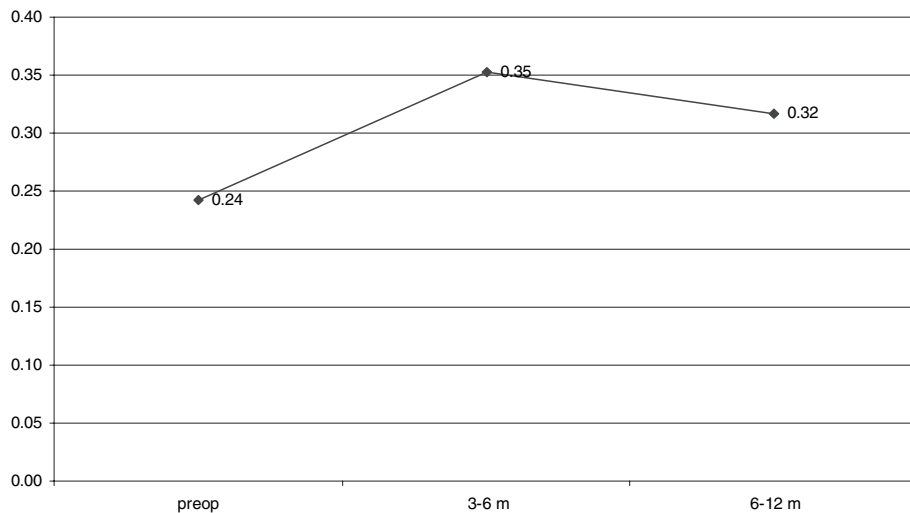
The influence of DME morphology on the results

The prognosis of DME was influenced by DME morphology.

- More eyes with DME type E2a gained 3 lines or more of VA among the DIODE Group (44%) when compared with the PPV Group (29%) and the IVT Group (40%), at least after 3–6 months of treatment. After 12 months or more, the percentage of eyes which gained 3 lines or more of VA decreased to 1% in the DIODE Group, 0% in the IVT Group, while it was still 14% in the PPV Group.

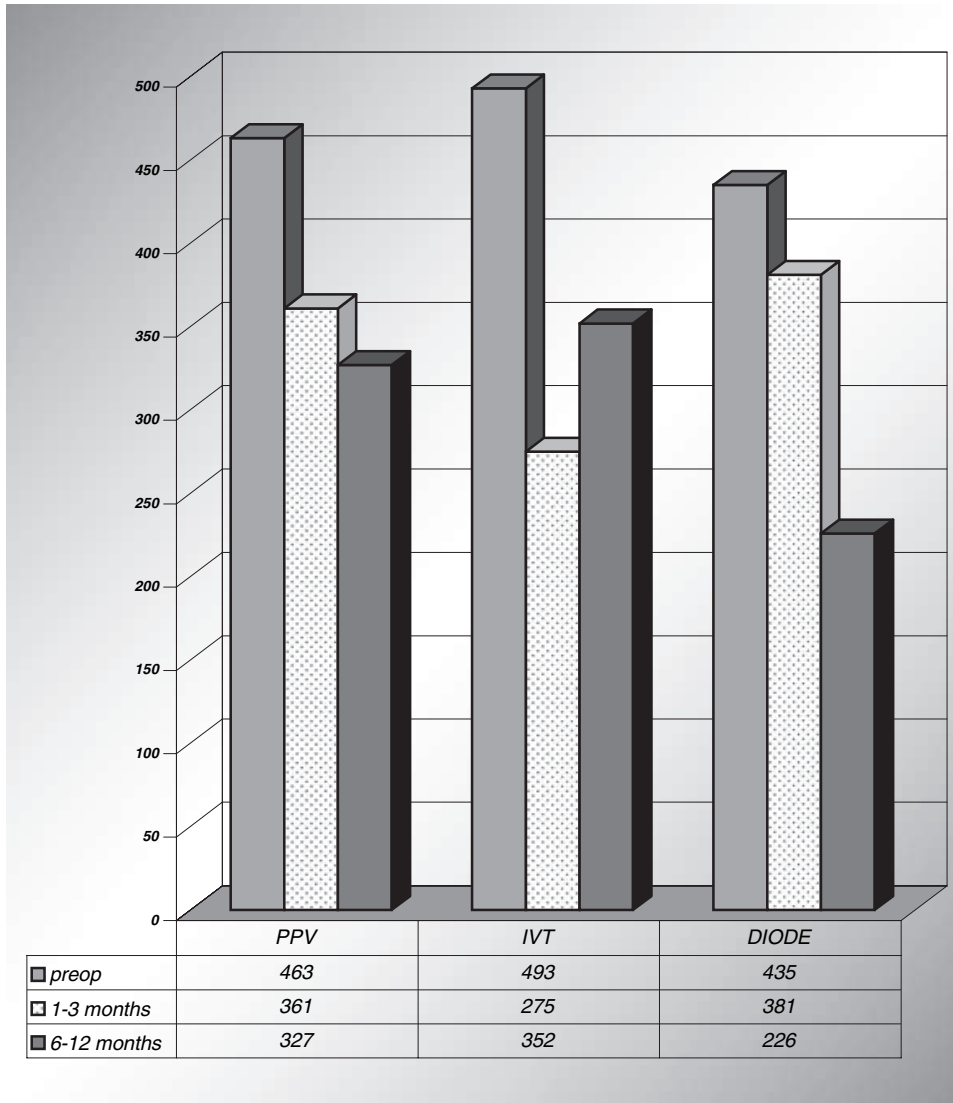


Graph 2. Percentage of eyes with a gain of 3 lines or more of VA in time per treatment groups.

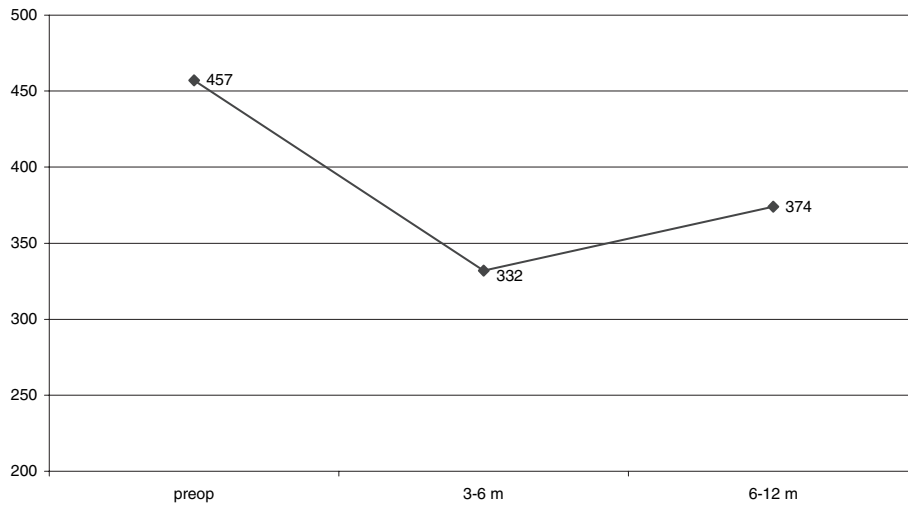


Graph 3. Change in the mean VA with time considering all the 169 eyes without differentiating the type of treatment.

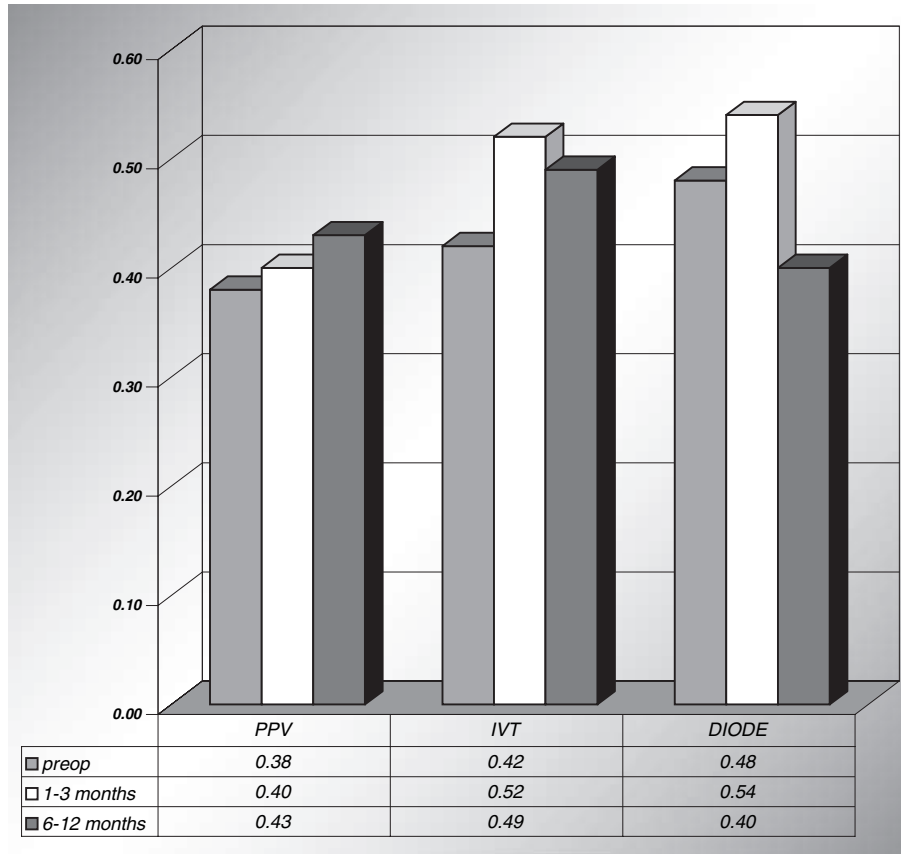
Semin Ophthalmol Downloaded from informahealthcare.com by Nyu Medical Center on 05/21/15 For personal use only.



Graph 4. Change in the mean foveal thickness with time per treatment group.



Graph 5. Change in the mean foveal thickness with time considering all the 169 eyes without differentiating the type of treatment.



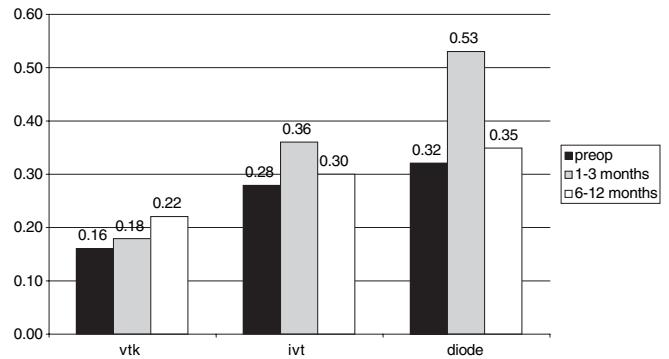
Graph 6. Change in the mean VA with time per treatment group, in a subgroup of eyes with preoperative VA ≥ 0.3 .

- Only PPV improved VA and foveal thickness in type E2c
- The prognosis was worse in the presence of E3 (neuroepithelial detachment) in all treatment groups. In fact less eyes gained 2 lines or more of VA. When E3 was present, an improvement in VA (Graph 7) and in retinal thickness (Graph 8) was appreciable only into the PPV Group.

Graph 9 indicates the change of VA in function of DME morphology in the whole group of 169 eyes independently from the treatment strategy. The graph 9 indicates that by treating earlier stages of DME, the final VA is better, as well as the graph 10 indicates that the final foveal thickness is lower than in advanced stages. It is interesting to observe that the stage E1 (simple thickening without cystoid degeneration), presumably the earliest stage, is not the stage with the best final results.

Stability

Vitrectomy proved to be the most stable treatment. A significant number of eyes into the PPV Group continued to improve vision with time up to 24 months after surgery. Intravitreal triamcinolone was very effective in improving

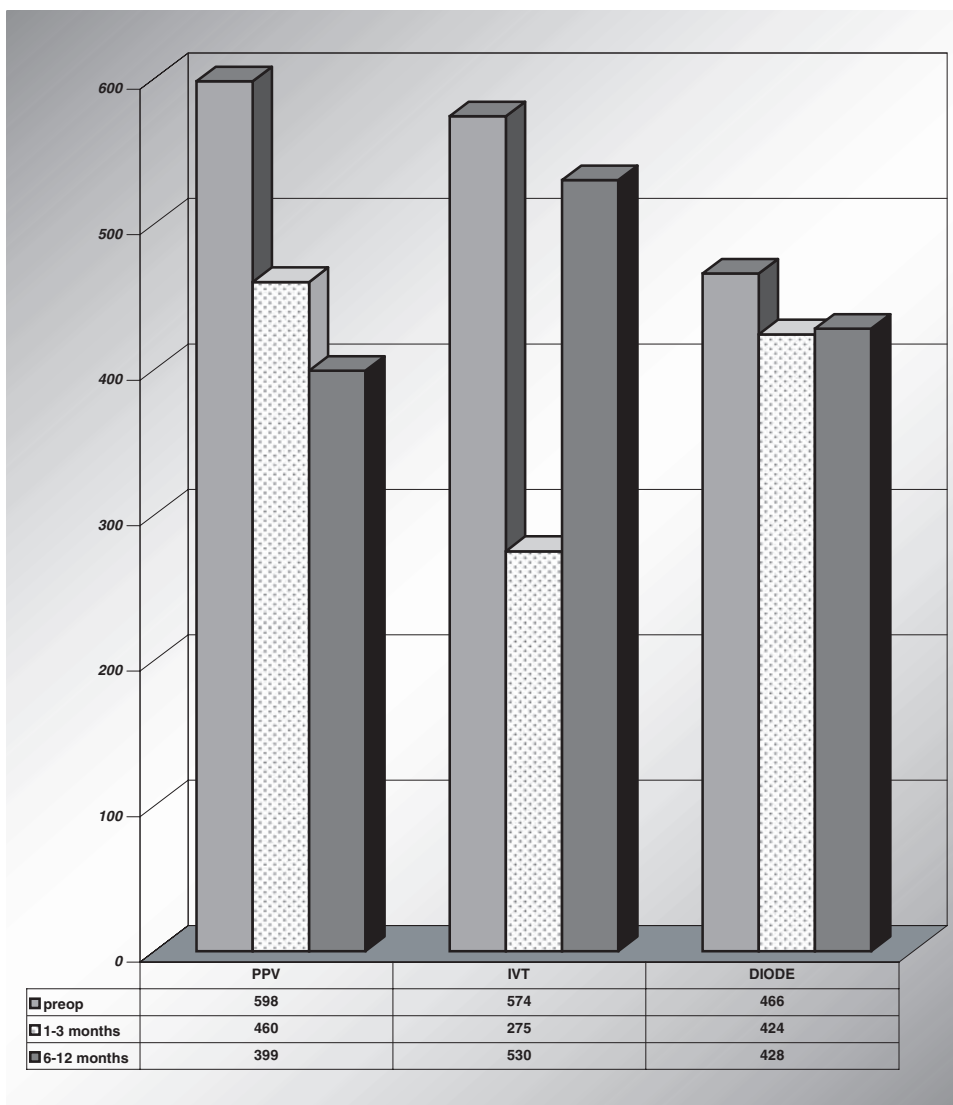


Graph 7. Change in the mean VA with time in dome with neuroepithelial detachment (E3).

VA and retinal thickness at 1–3 months but it was not stable and at 6–12 months the results faded away.

Preoperative PVD

Into the PPV Group, a subgroup of 6 eyes presented a pre-operative posterior vitreous detachment (PVD). The change in VA and in foveal thickness into this subgroup was compared with the PPV Group as a whole, in order to check whether the benefit of PPV could be detected only when the



Graph 8. Change in the mean foveal thickness with time per treatment group in a subgroup of eyes with presence of neuroepithelial detachment (E3).

posterior hyaloid was still attached to the retina or even in presence of preoperative PVD.

The change in VA (Graph 11) and in foveal thickness (Graph 12) in eyes with preoperative PVD was comparable with the PPV Group as a whole.

Complications

DIODE Group

Nor intra nor postoperative complications occurred into the DIODE Group.

PPV Group

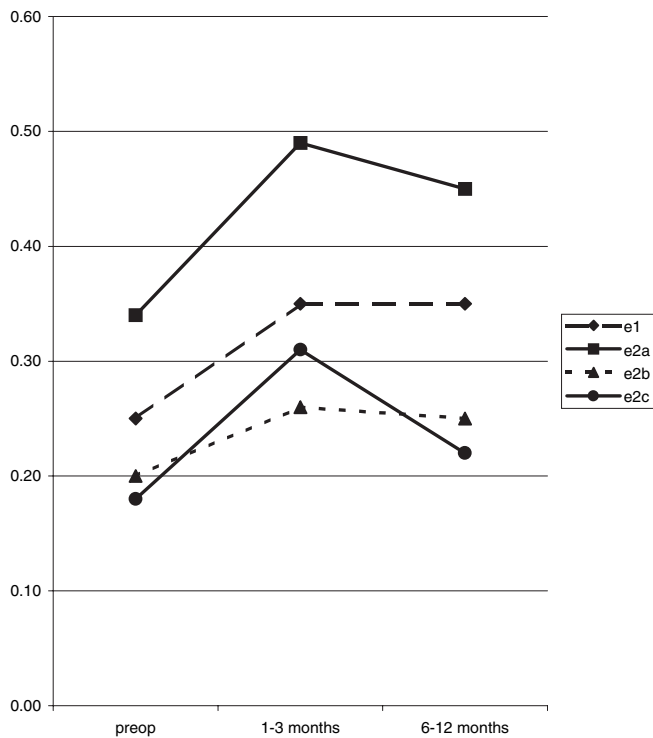
Among the PPV Group, during the first week after surgery, 90% of the eyes experienced a temporary increase of the

intraocular pressure (IOP) and 100% of the eyes a temporary decrease in VA.

Late postoperative complications (3 to 6 months after surgery) comprised a high incidence of cataracts (90% of the phakic eyes) and 3.4% of retinal detachment (2 eyes).

IVT Group

Among the IVT Group, no intraoperative complications occurred. As early postoperative complications (first week post-op), two eyes presented a pseudo-endophthalmitis with presence of fibrin into the anterior chamber but no hypopion and negative culture. At 1–3 months 8% of the eyes were in treatment for elevated IOP, 2 eyes (3.5%) received surgery for retinal detachment. At one year 15% of eyes presented a significant posterior cataract.



Graph 9. Change of VA with treatment in different types of DME according to the new macular edema classification.

Discussion

Photocoagulation is currently the main treatment for DME, but unfortunately the procedure typically results in stabilization and not in improvement in vision.

Absence of a fully successful treatment for DME has led to the search for alternative therapies.

The present study tested the effectiveness and safety of the three actual most widely accepted treatment strategies for dDME, laser photocoagulation (in our study with diode laser), intravitreal steroid injection and pars plana vitrectomy.

PPV, IVT and LASER were equally effective in lowering foveal thickness at 1–3 months but the results of PPV lasted longer, up to one year or more.

IVT seemed to be a possible solution, very well accepted by the patients and easy for the surgeons. But it was definitely not stable. The good results were lost in 5–7 months. The possibility of repeating IVT in the same eye twice a year or more often seemed limited in our opinion by the presence of complications.

The ETDRS study analyzed the percentage of eyes which gained 3 lines or more with laser vs no treatment, and found that only 3% of the eyes which received a laser grid may improve their vision of at least three lines.⁴ This percentage was much higher with every treatment tested in our study at least at 6 months of follow-up. After one year, the results obtained by the DIODE Group resembled the ETDRS

results, in fact only 4% of eyes showed a gain of 3 lines or more. Nine percent of eyes of the IVT Group showed the same gain in vision while after PPV 17% of eyes gained 3 lines or more of vision.

Therefore, the study may conclude that, even if the average VA does not change significantly in one year after any treatment, a relative high percentage of eyes improved their vision with PPV. PPV is the therapeutic strategy which helps more the patients with DME.

Many authors observed the discrepancy between the anatomical improvement of DME with treatment and the lack of improvement in VA.^{16,19} It is known that an important prognostic factor is the preoperative VA. Our study seemed to confirm that a better preoperative vision and a less severe edema could lead to a better improvement in vision especially with PPV.

Also morphology of DME classified preoperatively with OCT may help in guiding to the choice of treatment and as a prognostic factor.

In fact the study showed that by treating earlier stages of DME, the final VA was better, as well as the final foveal thickness was lower than in advanced stages. It is interesting to observe that the stage E1 (simple thickening without cystoid degeneration), presumably the earliest stage, was not the stage with the best final results.

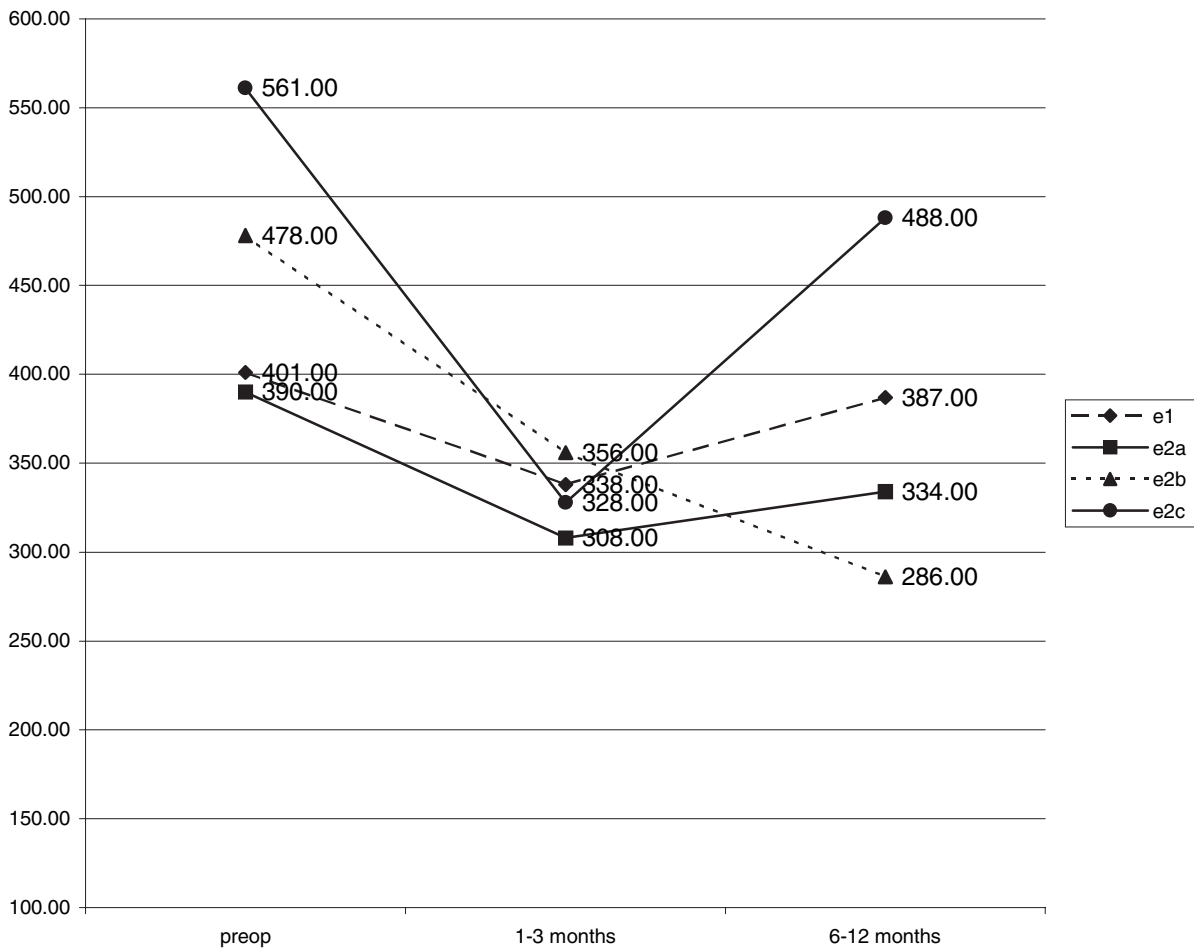
The authors interpreted this finding observing in different eyes that E1 may be both an authentic early stage of DME in eyes with good VA but also the final atrophic stage in eyes with very low VA and macular ischemia. It is obvious that these eyes hardly improve their vision after any kind of treatment.

Our study highlighted the effectiveness of PPV in improving VA and decreasing foveal thickness as well as the stability of a single PPV procedure with time. Also VA continued to improve in the same eye postoperatively with time. We found that the same results of the PPV Group were obtained in a subgroup of eyes with PVD already present preoperatively. Therefore, PPV probably does not work solely by relief of macular traction. The question remains, why does PPV relieve DME?

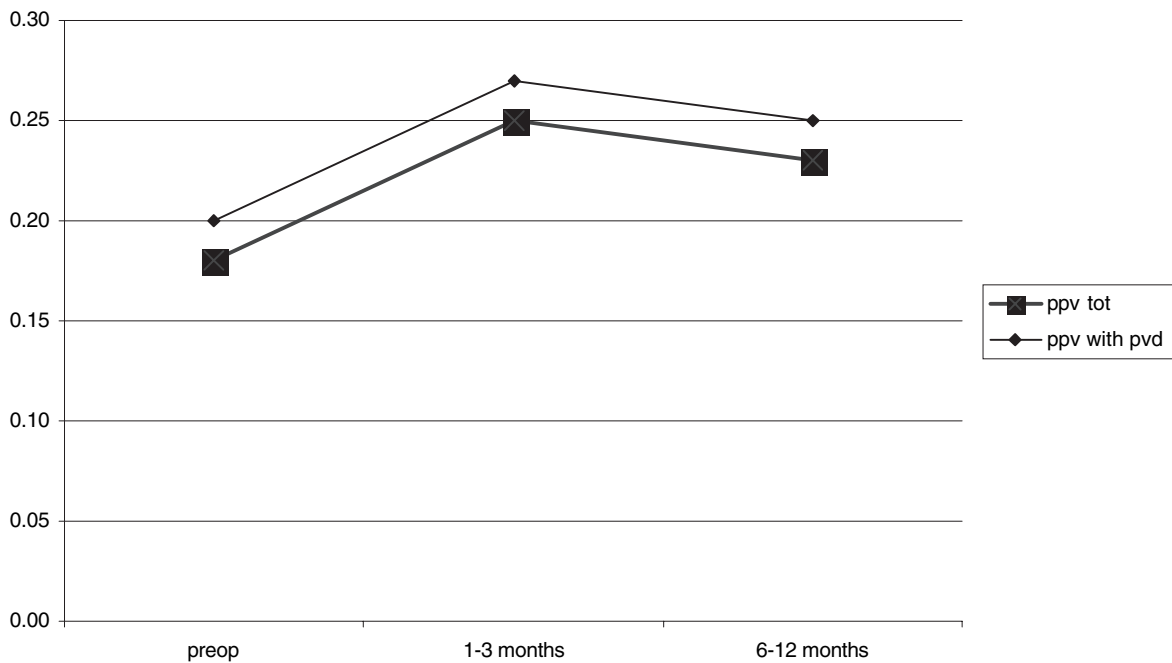
Otani¹⁶ stated that foveal thickness decreases even when the vitreous is still attached but without evident traction at OCT. PPV may not only release traction on the macula but also eliminate the condensed fluid containing chemical mediators in the pre-macular liquefied pocket.¹⁷

Stefansson *et al.*²⁹ gave another possible explanation. They demonstrated that preretinal oxygen tension was higher in vitrectomized eyes, because the aqueous humor, which is more oxygenated than vitreous fills the vitreous cavity after surgery. Furthermore, Kadonosho *et al.*³⁰ have shown an increased perifoveal capillary blood flow after PPV in his series.

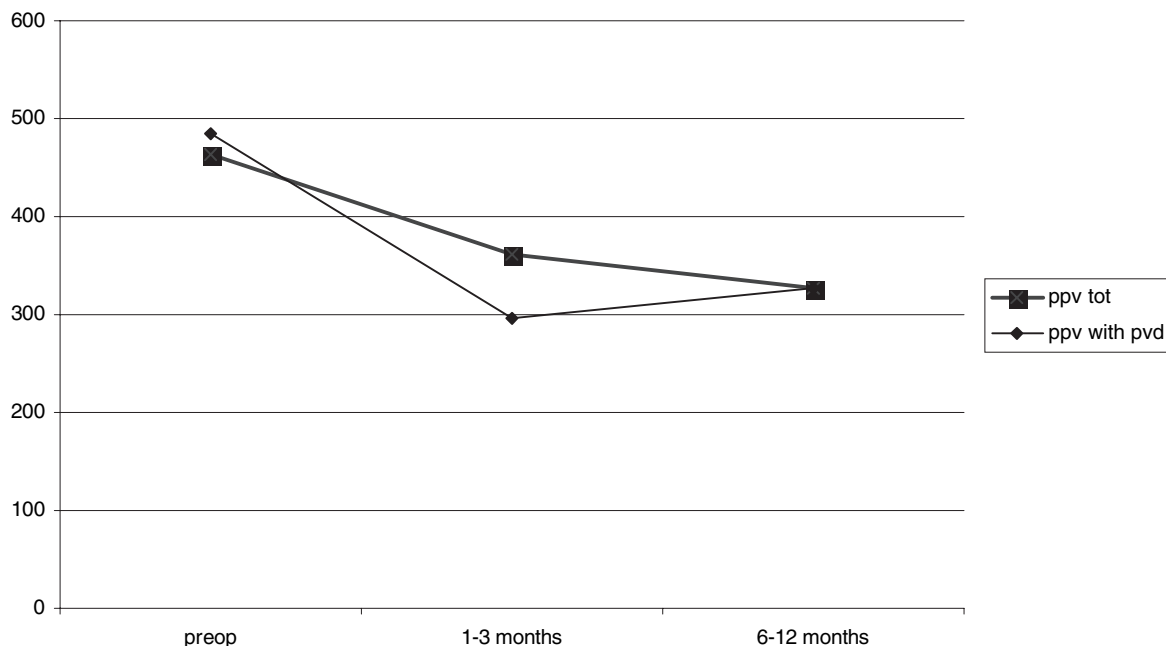
We think that given the major changes that may happen in the evolution of dDME, even after treatment, the minimal follow-up to judge the effectiveness of a treatment in any study is one year.



Graph 10. Change of foveal thickness with treatment in different types of DME according to the new macular edema classification.



Graph 11. Change in the mean VA with time in eyes treated with PPV. Comparison between the group as a whole (PPV tot) and a subgroup of eyes with PVD already present preoperatively (PPV with PVD).



Graph 12. Change in the mean foveal thickness with time in eyes treated with PPV. Comparison between the group as a whole (PPV tot) and a subgroup of eyes with PVD already present preoperatively (PPV with PVD).

New therapeutic flow chart

Taking into account the results of the study, the authors changed their personal guidelines in the treatment of diabetic macular edema:

Laser grid in eyes with

- Focal edema
- Early stages (E1, E2a) of dDME in eyes with VA ≥ 0.5

PPV in patients with

- Evident traction (T2, T3)
- Early stages (E1, E2a) of dDME in eyes with VA < 0.5 and advanced stages (E2b, E2c) of dDME with any VA
- Neuroepithelial detachment (E3)

No more IVT will be performed for dDME by the authors.

The choice of 0.5 as threshold VA was taken by the authors in light of the following considerations:

- the study has shown that by treating eyes with preoperative VA ≥ 0.3 the final functional and anatomical results are better
- the possible intra and postoperative complications may limit the indication of PPV in eyes with VA ≥ 0.5

The treatment of DME is a real challenge and still an expanding field.

Future studies are needed to provide further insights on the pathophysiology and the natural history of DME, and therefore guidelines for treatment.

References

1. Klein R, KB, Moss SE, Cruickshanks KJ. The Wisconsin Epidemiologic Study of Diabetic Retinopathy. XV. The long-term incidence of macular edema. *Ophthalmology* 1995;102(1):7–16.
2. Group R, Trial SR. A randomized trial of sorbinil, an aldose reductase inhibitor, in diabetic retinopathy. *Arch Ophthalmol.* 1990;108:1234–1244.
3. Ogura Y, KJ, Takahashi K, Honda Y. Visual improvement in diabetic macular edema by hyperbaric oxygen treatment. *Nippon Ganka Gakkai Zasshi.* 1988;92(3):1456–1460.
4. Group E.T.D.R.S.R. Photocoagulation for diabetic macular edema; early treatment diabetic retinopathy study report number 1. *Arch Ophthalmol.* 1985;103:1796–1806.
5. Bresnik G, Diabetic Maculopathy. A critical review highlighting diffuse macular edema. *Ophthalmology* 1983;90: 1301–1317.
6. Browning DJ, AA. The effect of the surgeon and the laser wavelength on the response to focal photocoagulation for diabetic macular edema. *Ophthalmology* 1999;106(2): 243–248.
7. Friberg RJ, aKE. The treatment of macular disease using a micropulsed and continuous wave 810-nm diode laser. *Ophthalmology* 1997;104:2030–2038.
8. Jonas JB, SA. Intraocular injection of crystalline cortisone as adjunctive treatment of diabetic macular edema. *Am J Ophthalmol.* 2001;132:425–427.
9. Massin P, AF, Haouchine B, Erginay A, Bergmann JF, Benosman R, Caulin C, Gaudric A. Intravitreal triamci-

- nonlone acetamide for diabetic diffuse macular edema: Preliminary results of a prospective controlled trial. *Ophthalmology* 2004;111(2):218–224.
10. Lewis HA, Blumenkranz GW, Campo MS, RV. Vitrectomy for diabetic macular traction and edema associated with posterior hyaloidal traction. *Ophthalmology* 1992;99(5):753–759.
 11. van Effenterre GG-A, Guiberteau C, Hany B, Lacotte I, JL. Macular edema caused by contraction of the posterior hyaloid in diabetic retinopathy. Surgical treatment of a series of 22 cases. *J Fr Ophtalmol.* 1993;16(11):602–610.
 12. Harbour JW *et al.* Vitrectomy for diabetic macular edema associated with a thickened and taut posterior hyaloid membrane. *Am J Ophthalmol.* 1996;121(4):405–413.
 13. Kalvodova BZ, J. Results of vitrectomy in cystoid diabetic macular edema detected by optical coherence tomography. *Cesk Slov Oftalmol.* 2002;58(4):224–232.
 14. Pendergast SD. Vitrectomy for diabetic macular edema associated with a taut premacular posterior hyaloid. *Curr Opin Ophthalmol.* 1998;9(3):71–75.
 15. Tachi N. Surgical management of macular edema. *Semin Ophthalmol.* 1998;13(1):20–30.
 16. Otani T, Kishi S. Tomographic assessment of vitreous surgery for diabetic macular edema. *Am J Ophthalmol.* 2000;129(4):487–494.
 17. Ikeda T *et al.* Vitrectomy for cystoid macular oedema with attached posterior hyaloid membrane in patients with diabetes. *Br J Ophthalmol.* 1999;83(1):12–14.
 18. Yang CM. Surgical treatment for severe diabetic macular edema with massive hard exudates. *Retina.* 2000;20(2):121–125.
 19. Sato Y, Lee Z, Shimada H. Vitrectomy for diabetic cystoid macular edema. *Nippon Ganka Gakkai Zasshi.* 2001;105(4):251–256.
 20. Takagi H *et al.* New surgical approach for removing massive foveal hard exudates in diabetic macular edema. *Ophthalmology* 1999;106(2):249–256; discussion 256–257.
 21. Hee MR, PC, Duker JS *et al.* Topography of diabetic macular edema with optical coherence Tomography. *Ophthalmology* 1998;105:360–370.
 22. Hee MR, PC, Wong C *et al.* Quantitative assessment of macular edema with optical coherence Tomography. *Arch Ophthalmol.* 1995;113:1019–1029.
 23. Hee MR, IJ, Swanson EA *et al.* Optical Coherence Tomography of the Human Retina. *Arch Ophthalmol.* 1995;113:325–332.
 24. Puliafito CA, HM, Lin CP *et al.* Imaging of macular diseases with optical coherence tomography. *Ophthalmology* 1995;102:217–229.
 25. Hee MR, PC, Wong C *et al.* Optical Coherence Tomography of macular holes. *Ophthalmology* 1995(102):748–756.
 26. Hee MR, BC, Puliafito CA *et al.* Optical coherence Tomography of age-related macular degeneration and choroidal neovascularization. *Ophthalmology* 1996;103:1260–1270.
 27. Wilkins JR, PC, Hee MR *et al.* Characterization of epiretinal membranes using optical coherence Tomography. *Ophthalmology* 1996;103:2142–2151.
 28. Schuman JS, P-KT, Hertzmark E *et al.* Reproducibility of nerve fiber layer thickness measurements using optical coherence Tomography. *Ophthalmology* 1996;103:1889–1898.
 29. Stefansson E. The therapeutic effects of retinal laser treatment and vitrectomy. A theory based on oxygen and vascular physiology. *Acta Ophthalmol Scand.* 2001;79(5):435–440.
 30. Kadonosono KI, Ohno NS. Perifoveal microcirculation before and after vitrectomy for diabetic cystoid macular edema. *Am J Ophthalmol.* 2000;130(6):740–744.