

---

## Correspondence

---

### To the Editor:

We read with interest the article “Indications and results of a new L-shaped macular buckle to support a posterior staphyloma in high myopia” by Parolini et al. *Retina* 2015;35:2469–82.<sup>1</sup> The authors compared results of macular buckling with vitrectomy to macular buckling alone in patients with myopic tractional maculopathy and found favorable results with buckling alone. There are few interesting parallels that we wish to draw.

Considering that authors had to explant 3 buckles after exposure, it would have been very interesting to note the response of macular tissue to buckle removal, that is if there was recurrence of myopic tractional maculopathy. As compared with conventional scleral buckling where success is dependent both on retinopexy and buckle indent, in myopic tractional maculopathy, results depend largely on buckle indent, and hence one would expect recurrences after buckle explant. Similarly, since buckle indent can be quantified on optical coherence tomography (OCT) in this particular series, it gives a great opportunity to follow-up the buckle indent over a period of time. Previous studies have reported failure in a small proportion of patients of retinal detachment who had been operated with scleral buckle without retinopexy.<sup>2</sup> These results were blamed on fading buckle indent or decreased height of the indent. Therefore, we encourage the authors to investigate longitudinal changes in buckle indent.

In patients with macular detachment, 40% of macular holes that failed to close in each group could be a result of “fish mouthing” that has been noted in earlier studies in patients of retinal detachment treated with scleral buckle.<sup>3</sup> This query could have been answered by comparing the minimum diameter of the macular holes sequentially before and after treatment. This would also help in titrating the buckle indent.

Another important aspect is the duration taken to achieve successful attachment, as the duration of macular disease<sup>4</sup> could affect the final outcomes. The authors of this study also mention the importance of “bringing retina and sclera close to each other for success”.<sup>4</sup> One would therefore expect quicker results with the combined approach.

Macular buckling indeed offers a new approach for management of myopic tractional maculopathy, and hence we keenly await the authors’ response.

Brijesh Takkar, MD

Shorya Azad, MS

Dr. Rajendra Prasad Centre for Ophthalmic Sciences,  
AIIMS, New Delhi, India

None of the authors have any financial/conflicting interests to disclose.

### References

1. Parolini B, Frisina R, Pinackatt S, et al. Indications and results of a new L-shaped macular buckle to support a posterior staphyloma in high myopia. *Retina* 2015;35:2469–2482.
2. Mahdizadeh M, Masoumpour M, Ashraf H. Anatomical retinal reattachment after scleral buckling with and without retinopexy: a pilot study. *Acta Ophthalmol* 2008;86:297–301.
3. Das T, Namperumalsamy P. Wedge scleral buckling in prevention of fish mouth phenomenon in retinal detachment surgery. *Indian J Ophthalmol* 1987;35:349–352.
4. Boyer DS, Nguyen QD, Brown DM, et al. Outcomes with as-needed Ranibizumab after Initial Monthly Therapy: long-term outcomes of the phase III RIDE and RISE Trials. *Ophthalmology* 2015;122:2504–2513.

---

### Reply

#### To the Editor:

We would like to thank Dr. Brijesh and Shorya for their interest and response to our article “Indications and results of a new macular buckle to support a posterior staphyloma in high myopia.”<sup>1</sup> The original article compared the results of macular buckling with vitrectomy versus macular buckling alone, in patients with myopic traction maculopathy.

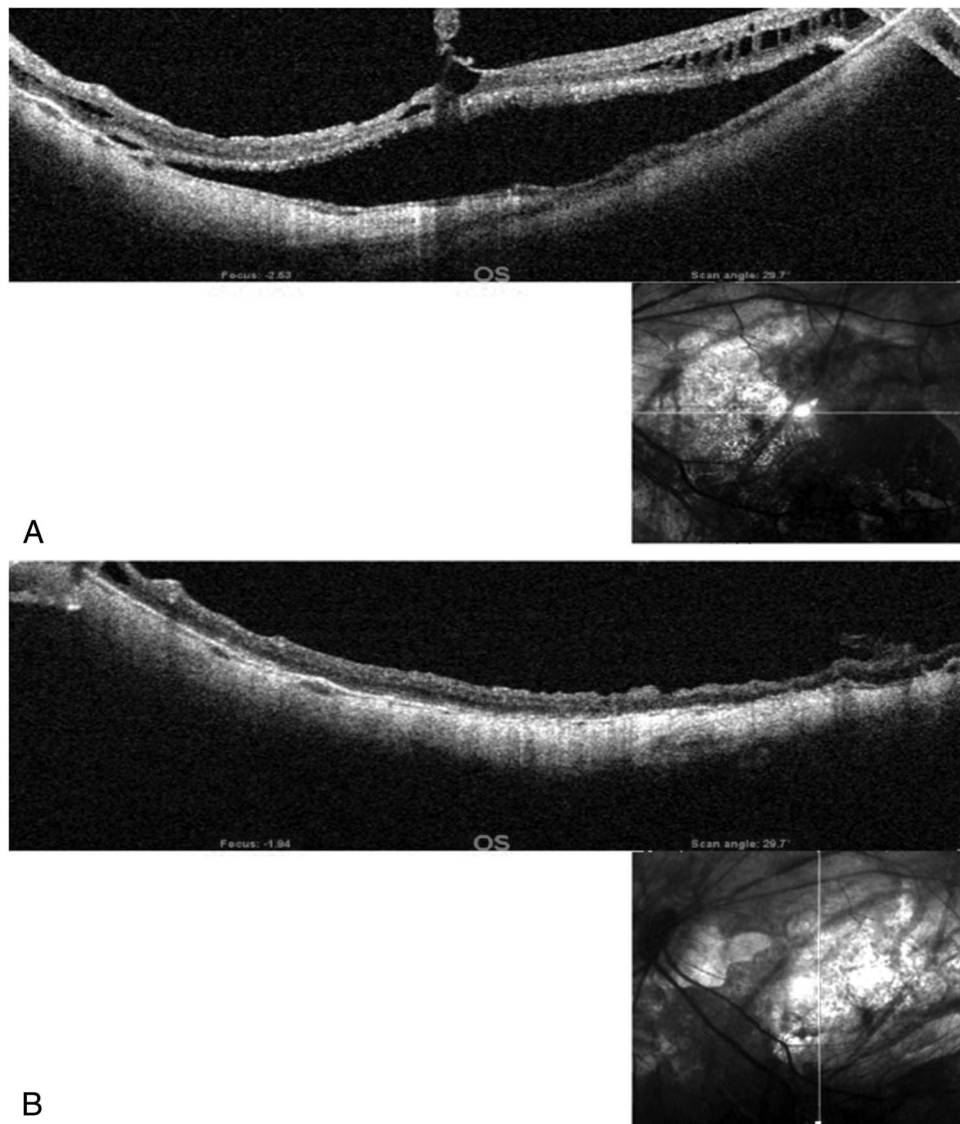
Brijesh and Shorya commented on four major points:

#### Point A

Since 3 buckles were explanted, Brijesh and Shorya asked us what the response of macular tissue to buckle removal was.

We did not notice a recurrence of myopic traction maculopathy after buckle removal, very likely because the removal was performed at least 6 months after implanting the buckle. Although there is no retinopexy and the result is dependent on the presence of the buckle, we explain the permanent indentation only due to a fibrotic capsule that forms around the buckle and remains after buckle removal.

The following figures depict a patient with macular detachment (Figures 1, A and B and 2, A–C) preoperatively and after removal of the buckle. A permanent indentation on the sclera remains after buckle removal.



**Fig. 1. A.** The figures depict a patient with macular detachment. **B.** Same patient as in A, after macular buckle and vitrectomy surgery, and after removal of the macular buckle. The effect on the release of traction is visible, and a more horizontal profile of the sclera remains, although the buckle is not present.

**Point B**

Brijesh and Shorya asked us what the results of buckle indentation in the long term (more than 1 year) were.

We have noticed that the effect on the sclera remains even after a long follow-up. We took optical coherence tomography and measured the axial length of the patients, preoperatively and after a long-term follow-up (at least 12 months after surgery). Postoperative axial length does not change.

Figure 3, A–C shows the optical coherence tomography of a patient preoperatively, 2 months, and 9 months, respectively, after surgery.

**Point C**

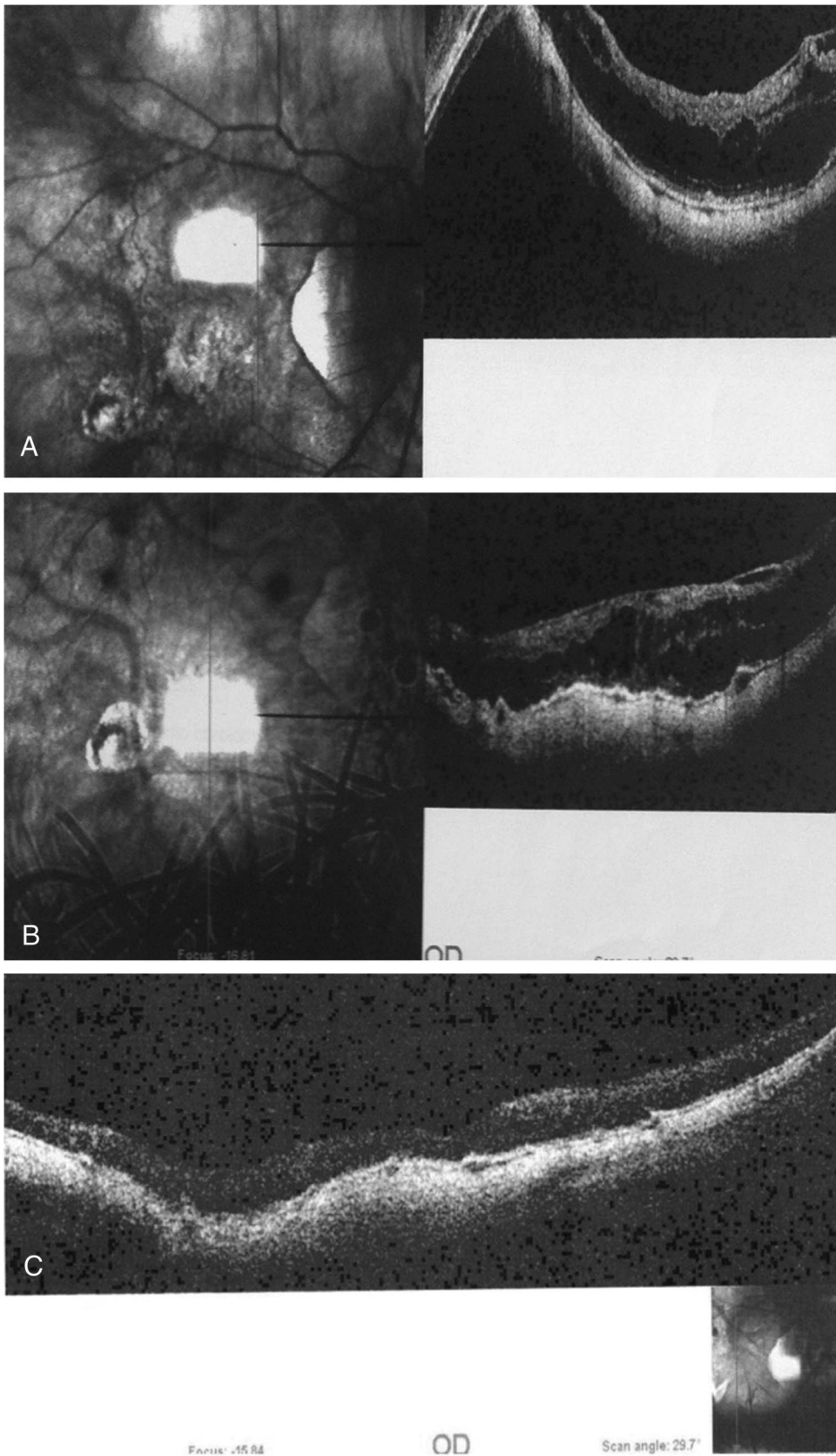
Brijesh and Shorya asked us if the lack of closure of some macular holes was due to fish mouth effect after buckle.

We have not observed a fish mouth effect after buckling a macular detachment secondary to macular hole. We assumed that some holes do not close either for their large preoperative measure (unfortunately we do not have the preoperative measurements) or for lack of intraoperative manoeuvres on the hole itself to ease the closure (Figure 4, A and B).

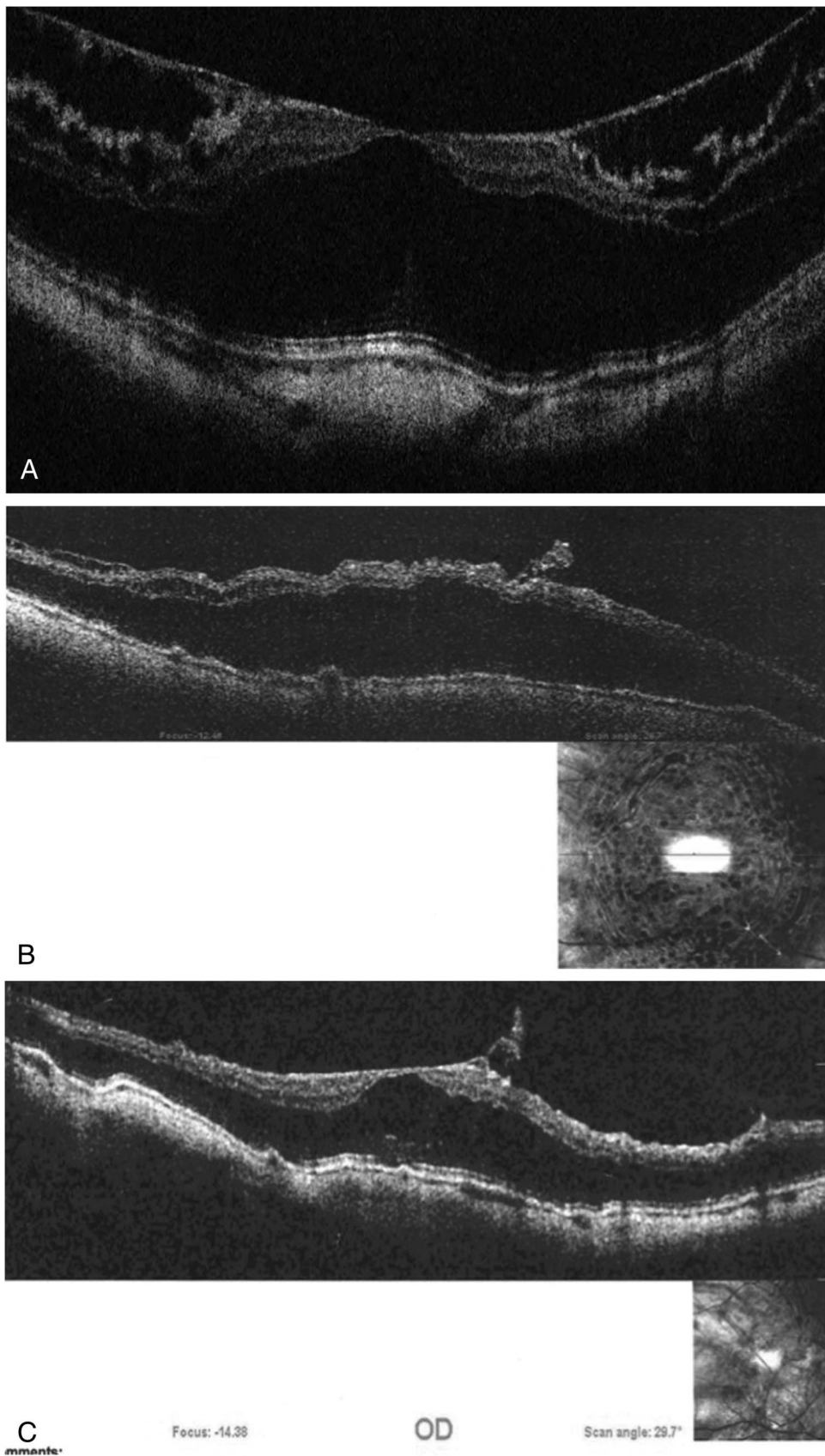
**Point D**

Brijesh and Shorya asked us what the duration taken to achieve successful attachment was in the two groups, combined and noncombined surgery.

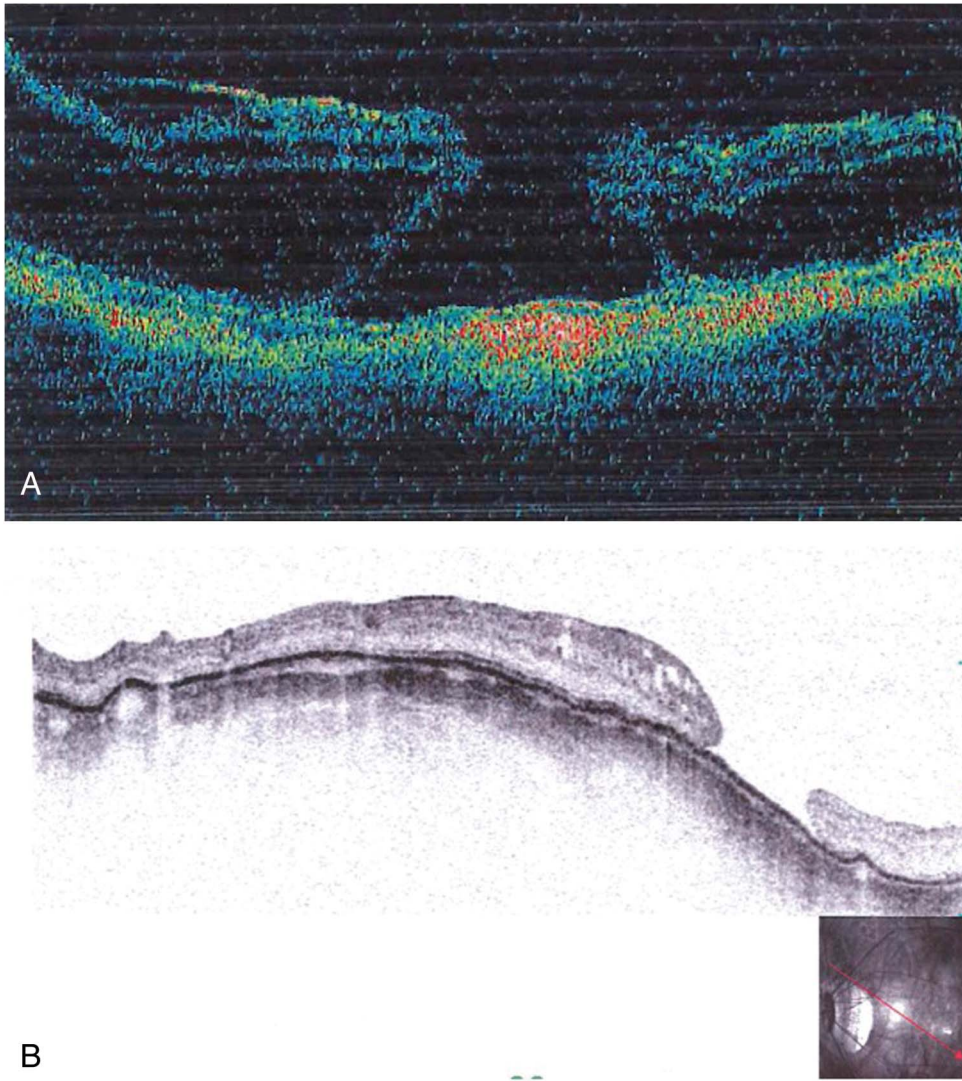
Combined surgery guarantees a quicker resolution of myopic traction maculopathy. However, the amount of improvement in best corrected visual acuity was not significantly different in the two



**Fig. 2.** A. Patient with macular detachment. B. Same patient as in A, with macular detachment treated with macular buckle. The scleral indentation is visible in the central part of the optical coherence tomography scan. C. Same patient as in A, with macular detachment treated first with macular buckle. The buckle was removed for external extrusion. Simultaneously vitrectomy was added. The scleral indentation is, however, still visible in the central part of the optical coherence tomography scan.



**Fig. 3.** **A.** Patient with retinoschisis preoperatively. **B.** Same patient as in **A** with retinoschisis 2 months after macular buckle. The indentation is visible under the central part of the sclera and a partial relief of retinoschisis is shown. **C.** Same patient as in **A**, with retinoschisis 9 months after macular buckle. The indentation is visible under the central part of the sclera. The retinoschisis shows progressive relief and visual acuity has improved from 20/100 to 20/25.



**Fig. 4.** A. Patient with retinoschisis and full thickness macular hole. B. Same patient as in A, after vitrectomy combined with macular buckle. The figure shows resolution of the retinoschisis and full thickness macular hole. The hole is flat and open but no fish mouth effect is observed.

groups when comparing patients with at least one year follow-up.

Barbara Parolini, MD  
 Federico Noto, MD  
 Daniele Cardillo, MD  
 Sajish Pinackatt, MD  
 Department of Ophthalmology,  
 S. Anna Hospital, Brescia, Italy

None of the authors have any financial/conflicting interests to disclose.

#### Reference

1. Parolini B, Frisina R, Pinackatt S, et al. Indications and results of a new Lshaped macular buckle to support a posterior staphyloma in high myopia. *Retina* 2015;35:2469–2482.

---

#### Correspondence

##### To the Editor:

We read with great interest the article “The ‘PITCH-FORK SIGN’: A Distinctive Optical Coherence Tomography Finding in Inflammatory Choroidal Neovascularization” by Hoang et al<sup>1</sup> *Retina*. In the article, the authors reported on a total of four eyes, belonging to four young female patients affected by inflammatory choroidal neovascularization (CNV). Choroidal neovascularization is a rare complication of vitelliform macular dystrophy in pediatric patients. It seems to occur in approximately 5% of affected eyes,<sup>2</sup> and the etiology is not typically inflammatory.<sup>3</sup> In each case, imaging revealed multiple distinctive finger-like projections extending to the outer retina. These projections are referred to by the authors as the “pitchfork sign”