

See discussions, stats, and author profiles for this publication at: <https://www.researchgate.net/publication/8073390>

Diabetic macular edema: An OCT-based classification

Article in *Seminars in Ophthalmology* · March 2004

DOI: 10.1080/08820530490519934 · Source: PubMed

CITATIONS

45

READS

4,065

7 authors, including:



Giacomo Panozzo

Azienda ULSS numero 22 Bussolengo

21 PUBLICATIONS 489 CITATIONS

SEE PROFILE



Barbara Parolini

Istituto Clinico S.Anna

36 PUBLICATIONS 608 CITATIONS

SEE PROFILE



Elena Gusson

Azienda Ospedaliera Universitaria Integrata V...

9 PUBLICATIONS 159 CITATIONS

SEE PROFILE



Andrea Mercanti

Azienda Ospedaliero Universitaria Santa Mari...

6 PUBLICATIONS 366 CITATIONS

SEE PROFILE

Diabetic macular edema: an OCT-based classification

Panozzo G., Parolini B., Gusson E., Mercanti A., Pinackatt S., Bertoldo G. and Pignatto S.

Teclò, Vitreoretinal Service, Verona – Italy

Abstract

Purpose. More than ten years after ETDRS, Optical Coherence Tomography (OCT) greatly enhanced our ability to detect macular thickening and has brought new insights on the morphology of edema and on the presence of vitreal traction.

In this study we propose a new classification of macular edema based on OCT findings to better catalogue and follow this complex clinical entity.

Methods. Since January 2000 we analysed with OCT 2 (Zeiss Inc.) more than one thousand and two hundred eyes with DME.

Results. The classification takes into account five parameters: retinal thickness, diffusion, volume, morphology and presence of vitreous traction. Standard figures and numerical values for every parameter are given.

Conclusion. Although ETDRS guidelines for laser treatment of DME still remain the only proven therapy for this condition, many other strategies are now on trial, and the vast majority of authors use OCT as the best indicator of therapeutic benefit.

The amount of information given by OCT demonstrates that macular edema is a complex clinical entity with various morphology and gravity, and disclaimed the limitations of a simple “clinical” definition.

As in many other examples such as macular holes and choroidal neovascularization, a uniform and precise definition of macular edema would increase the possibility to compare and judge the result of different therapeutic strategies.

Aim of this classification is to implement the ETDRS clinical definition of DME with the precise and useful data given by OCT to better diagnose, catalogue and follow macular edema.

Introduction

ETDRS defined diabetic macular edema (DME) as focal or diffuse retinal thickening in the macular area. When this thickening involves or threatens the fovea, it is defined as “clinically significant” and laser treatment is indicated to reduce progressive visual loss.

Following ETDRS guidelines, diagnosis and follow up of macular thickening is made by biomicroscopy, and fluorescein angiography is subsequently used to guide laser treatment.

Ten years after ETDRS, Optical Coherence Tomography (OCT) greatly enhanced our ability to detect macular thickening and has brought new insights on the morphology of edema and on the presence of vitreal traction.

Although ETDRS guidelines for laser treatment of DME still remain the only proven therapy for this condition, other strategies have been proposed or are now on trial, and OCT is becoming the preferred indicator of therapeutic benefit through a precise measurement of variation in retinal thickness.

The amount of information given by OCT not only underscored the limitations of a clinical definition of macular edema, it also demonstrates that macular edema is much more than “retinal thickening”: it is a complex clinical entity with various morphology that have to be precisely described in order to choose the correct therapeutic approach and understand its potential benefits.

As for other pathologies such as macular hole or choroidal neovascularization, a uniform and precise definition of macular edema would also increase the possibility to compare different therapeutic strategies.

In this study we organized the data on macular edema given by OCT in a simple classification that takes into account five parameters: retinal thickness, extension of retinal thickening, macular volume, retinal morphology and vitreoretinal relationship. Although it is specific to diabetes,

Correspondence: Giacomo Panozzo, MD, Teclò Vitreo-Retinal Services, Via Del Perlar 2, Verona 37135, Italy. E-mail: g.panozzo@iol.it

this classification can also be used for all kind of macular edema.

Methods

From January 2000 to April 2003, we analyzed with OCT 2 (Zeiss Inc.) more than 1200 eyes with DME. Categories and parameters included in this classification are the result of this experience.

OCT

Optical Coherence Tomography (OCT) is a digital optical instrument that generates cross sectional images (tomograms) of the retina by optical-coherence interferometry, a procedure analogous to ultrasound, except for using light (a broad bandwidth near-infrared light beam at 840 nm) rather than sound, and measures the echo delay time of light reflected and backscattered from the retina. This method permits non-contact measurement of structures on a 10 micron scale, versus the 100-micron scale of ultrasound.

The system is interfaced to a video-slit lamp biomicroscopy that provides a real-time view of the fundus and of the scanning probe beam.

Retinal morphology

Each scan pass can be spatially oriented and varied in length throughout the posterior pole. OCT delineates intraretinal, cross-sectional anatomy with axial resolution of about 10 microns by taking an A-scan consisting of 1024 data points over 2 mm of depth. Cross-sectional or B-mode imaging is accomplished in 2.5 seconds by acquiring a sequence of 100 A-scans while scanning the probe beam across the retina.¹ The axial data points are then used to construct a cross sectional image (tomogram) of retinal anatomy, presented in real time using a false color scale that represents the degree of light backscattering from tissues at different depths in the retina. These images can be stored and later analyzed by various modalities.

Scan images are presented expanding twice the image vertically, in order to allow the viewer to perceive more detail throughout the longitudinal plane of the retina.

Regarding vitreoretinal relationship, OCT can visualize only pre-retinal echoes close to the inner retinal surface at a maximal distance of about 400 microns. Vitreoretinal connection within the macular area or at the optic disk, as well as minimal elevations of the posterior hyaloid can therefore be easily visualized and followed but only for a limited distance from the retinal surface.

Retinal thickness

The retinal thickness is calculated by the software program from the inner retinal surface to the inner border of the

hyper-reflecting line corresponding to the retinal pigment epithelium.

Scan acquisition and analysis

All the parameters utilized in this classification are acquired by a scan pattern called “Radial Lines”, and then analyzed by the option “Retinal Map”.

Retinal morphology and vitreoretinal relationship are then visualized by the option “align and normalize”.

1. Radial lines

This modality performs six 6 mm scans centered at the fixation point like spokes on a wheel. The first scan is vertical and the others are taken every 30° clockwise, for a total of 600 points of retinal thickness measurements, mostly concentrated in the foveal area.

2. Retinal map

Retinal thickness is computed separately for each of the 600 points of measurement, and this information is used to construct a two dimensional map of retinal thickness over the circular region of 6 mm of diameter spanned by the scans. Resembling an ETDRS map of macular area, this map (Fig. 2) is divided into one central area of 1.0 mm, and two concentric peripheral rings of 3 mm and 6 mm, respectively. Two oblique lines divide each of the two rings in four quadrants for a total of 9 areas (central area plus four areas for each ring). Two maps are given: numerical and color-coded.

This function analyzes the six Radial Lines giving the following numerical parameters:

- a. *Retinal Thickness at the fixation point.* Mean value of the six measurements at point of fixation of the six radial scans. A standard deviation reflects the difference of the six measurements taken by the six radial lines.
- b. *Retinal Thickness of the nine macular areas.* For each area a mean value is given without standard deviation.
- c. *Retinal Volume.* Total volume of the macular area (macular map) calculated from the all measurements of the six radial lines.

3. Align and normalize

We evaluated retinal morphology and vitreoretinal relationship from the analysis of all the six scan of the “Radial Lines” modality. Every scan was visualized and evaluated after correcting image with the “align and normalize” option. “Align” corrects the data for effects due to patient motion in the axial direction, and “Normalize” eliminates background bias respect to noise and signal strength.

Results

The OCT Classification considers five parameters:

1. retinal thickness
2. volume
3. morphology
4. diffusion
5. epiretinal traction

Retinal thickness (RT)

Retinal thickness is taken for the fixation point, for the central macular zone, and cumulatively for the perifoveal and peripheral areas. The numerical values of RT are taken from the “Eye Information Table” for fixation point and from the numerical map for the nine macular areas.

RT values are classified as:

1. normal
2. borderline
3. edema (definite thickening)
 1. Fixation Point: thickness at the point of fixation, as reported in the Table “Eye Information” of the Retinal Map.

Normal:	150 ± 20 μ
Borderline:	170–210 μ
Edema:	≥ 210 μ
 2. Central Zone:

Normal:	170 ± 20 μ
Borderline:	190–230 μ
Edema:	≥230 μ
 3. Perifoveal and peripheral areas:

Normal:	230 ± 20 μ
Borderline:	250–290 μ
Edema:	≥290 μ

Extension

The zones with retinal thickness over borderline values are recorded to give information on the extension of the edema.

Clinically Significant Macular Edema (CSME). According to ETDRS parameters, CSME corresponds to a RT ≥ 300 μ involving the central zone and/or a RT > 320 μ the 1st ring.

Edema confined to the 2nd ring has not been considered clinically significant.

Volume

This parameter is not essential to the diagnosis of edema; however, it offers important data on thickness of macular area considered as a whole.

The data are meaningful only for diffuse edema involving at least the center and the 1st ring, and not for focal edema.

- | | |
|-------------|---------------------------|
| Normal: | 6.5 mm ³ ± 1 |
| Borderline: | up to 8.0 mm ³ |
| Abnormal: | ≥8.0 mm ³ |

Morphology

Standard images are given to ease the identification of various morphologies.

Three main morphologies are recognized:

- E1: simple thickening**
- E2: cystoid thickening (increasing severity from a to c)**
- E3: neuroepithelial detachment**

Each category can be present isolated or in association.

E1: simple thickening (Fig. 1: standard picture for E1).

Compact retinal thickening without clinically visible cystoid spaces.

E2: cystoid thickening. Retinal thickening associated with cysts, defined as circular or ovoid space with no reflectivity with minimum horizontal diameter of 150 μ and minimum vertical diameter of 300 μ as measured by manual caliper. The difference between horizontal and vertical dimension of the cysts is derived from the characteristics of software program (see above).

E 2a: mild (Fig. 2: standard picture for E2a). Retinal thickening associated with 2–4 central small cysts (horizontal diameter 150–200 μ, vertical diameter ≤400 μ)

E 2b: intermediate (Fig. 3: standard picture for E2b). Retinal thickening associated with cysts with petaloid configuration or with central big cysts (horizontal diameter ≤300 μ, vertical diameter ≤600 μ).

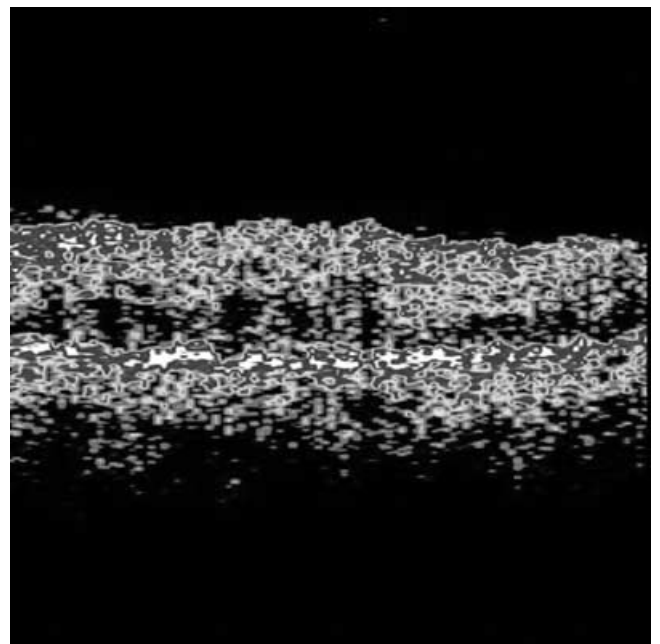


Figure 1. Standard picture for E1. Simple Retinal Thickening.

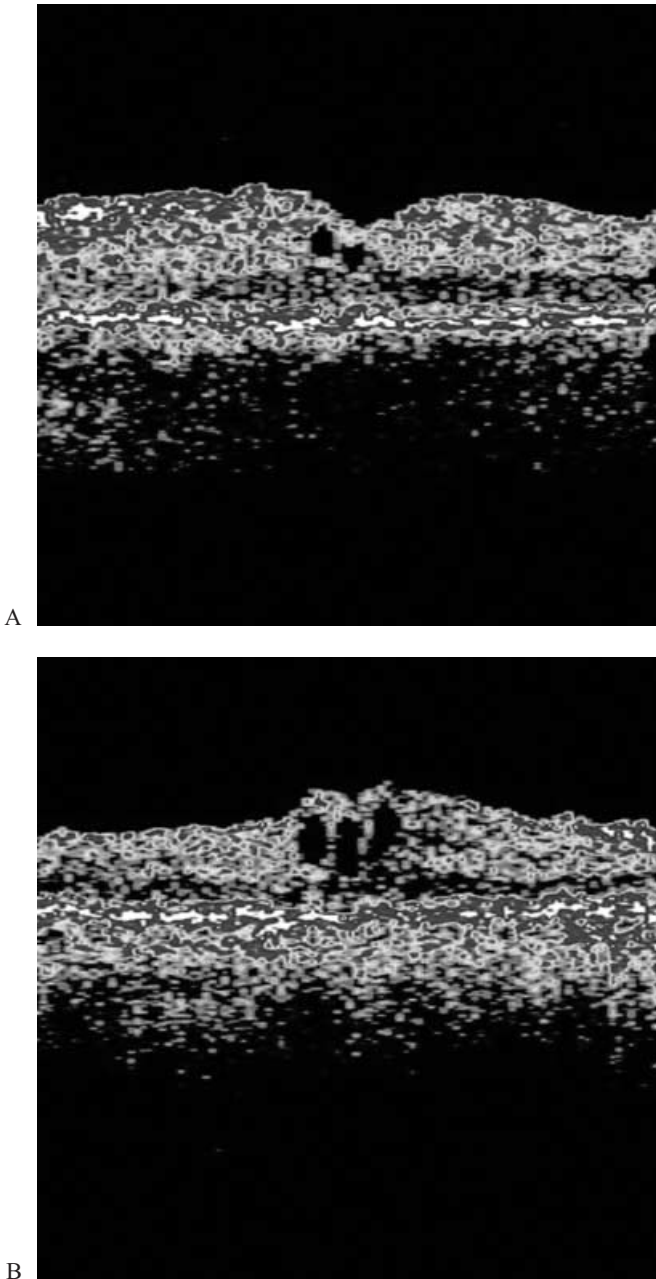


Figure 2. Standard picture for E2a: minimum (Fig. 2a) and maximum (Fig. 2b) for Mild Cystoid Edema.

E 2c: severe (Fig. 4: standard picture for E2c). Retinal thickening associated with coalescence of cysts with retinoschisis appearance.

E3: neuroepithelial detachment (Fig. 5: standard picture for E3). The retina is detached by the presence of sub-retinal liquid (non-reflecting space) above the hyper-reflecting line of the pigmented epithelium. This detachment can be isolated or associated with simple or cystoid retinal thickening.

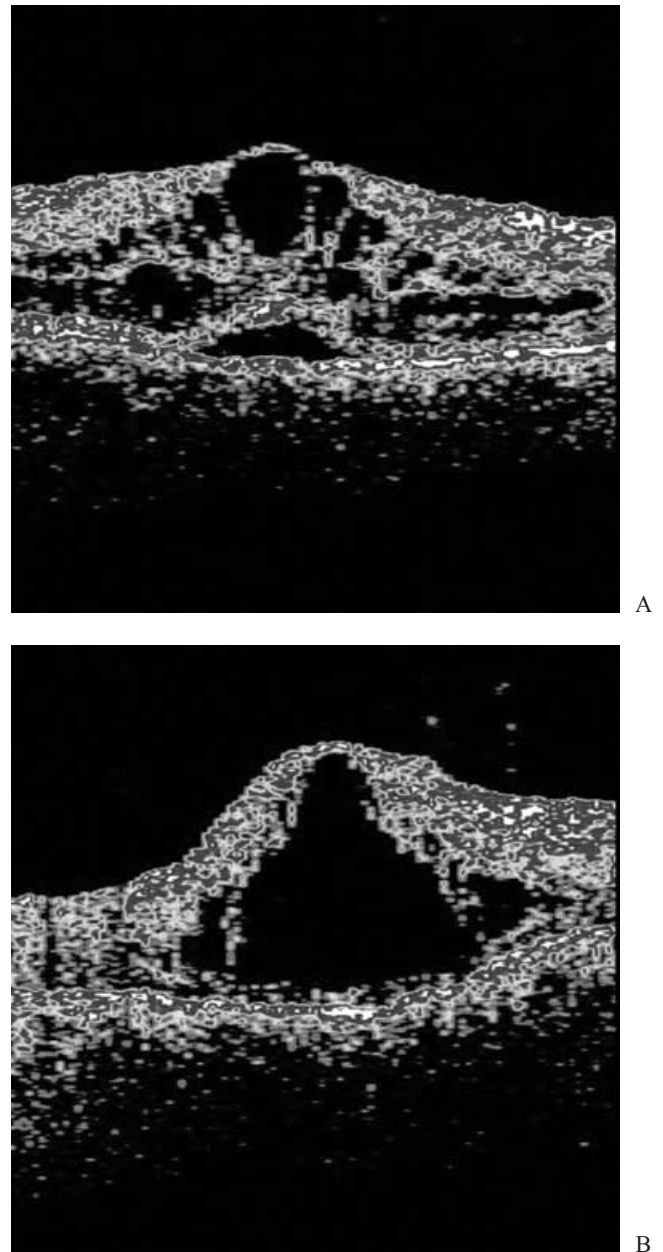


Figure 3. Standard picture for 2Eb. Intermediate cystoid macular edema. Retinal thickening associated with cysts with petaloid configuration (Fig. 3a, associated with small neuroretinal detachment-type E3) or with central big cysts of horizontal diameter $\leq 300\mu$ and vertical diameter $\leq 600\mu$ (Fig. 3b).

Epiretinal traction

Presence of well-defined and continuous hyper-reflecting line over the inner retinal surface with at least one point of adhesion to the retina in at least one of the six scans of the retinal map.

Four grades of increasing severity are given:

T0: absence of epiretinal hyper-reflectivity

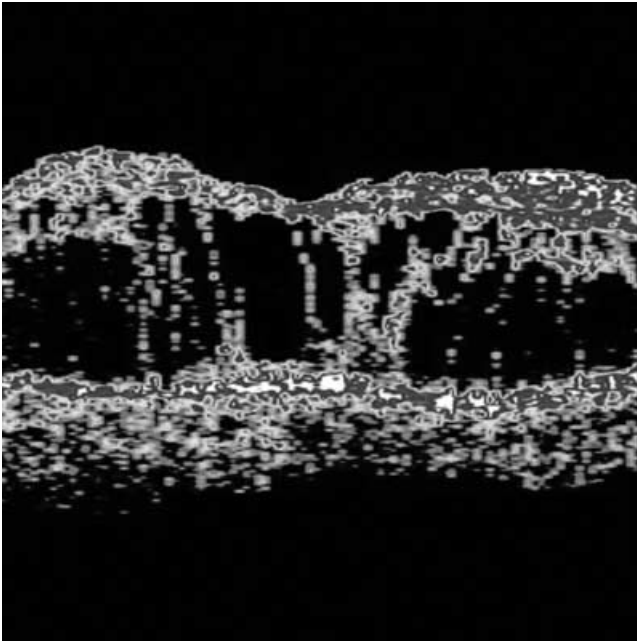


Figure 4. Standard picture for E2c. Severe cystoid macular edema with coalescence of cysts with retinoschisis appearance.

- T1: presence of a continuous line of flat hyper-reflectivity and adherent to the retina without significant retinal distortion (Fig. 6: standard picture for T1)
- T2: presence of continuous line of hyper-reflectivity with multiple points of adhesion to the retina and with significant retinal distortion (Fig. 7: standard picture for T2).
- T3: antero-posterior traction with “gull wings” configuration (Fig. 8: standard picture for T3).

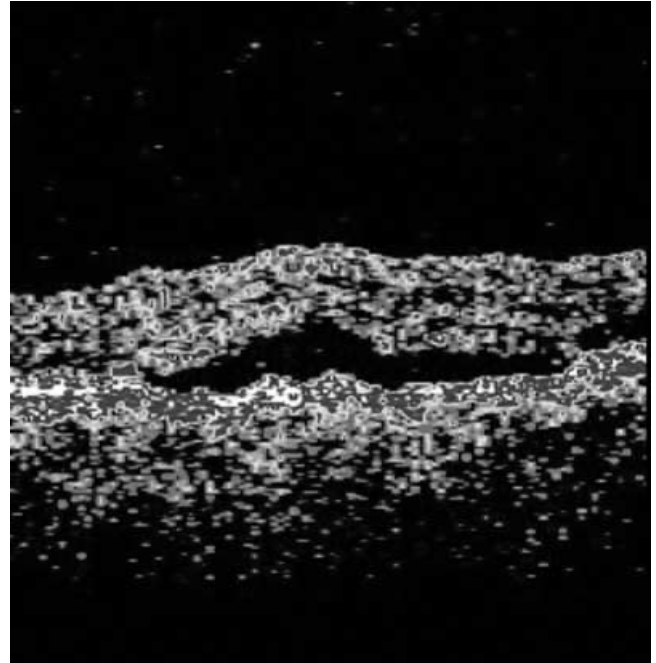
Discussion

Although biomicroscopy and FA remain the common diagnostic tools to examine the macular area, OCT, giving reliable, precise and reproducible retinal images is now becoming a widespread test for evaluation of the fine intraretinal structure and vitreoretinal panoramy.

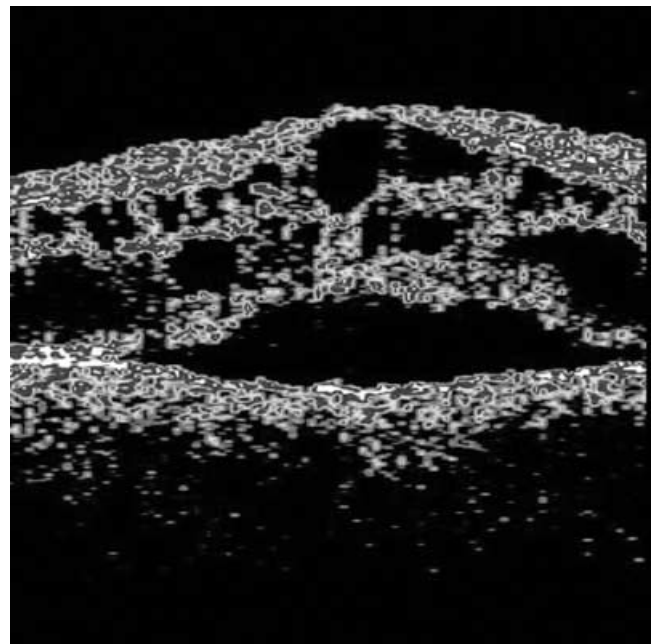
Regarding macular edema, OCT analysis demonstrates that this is a complex clinical entity with different patterns, extent, of progression, and possible abnormal vitreoretinal relationships.

In light of this knowledge, a classification only based on biomicroscopical evidence of retinal thickening seems to be insufficient to precisely describe macular edema and also to judge and compare different therapeutic strategies. The need to use quantitative and standardized methods to detect and monitor macular edema has been advocated by many authors, especially for clinical reports or trials.

In this work we catalogue all the information on macular edema given by OCT in a simple and clinically useful classification.



A



B

Figure 5. Standard picture for E3: neuroepithelial detachment. The retina is detached by the presence of subretinal liquid (non-reflecting space) above the hyper-reflecting line of the pigmented epithelium. This detachment can be isolated (Fig. 5a) or associated to simple or cystoid retinal thickening (Fig. 5b).

Aim of this classification is three-folds:

1. *defining macular edema with quantitative and reproducible measurement of retinal thickening.*
2. *cataloguing different stages of intraretinal edematous anomalies*
3. *adding vitreoretinal relationship to the description of edema*

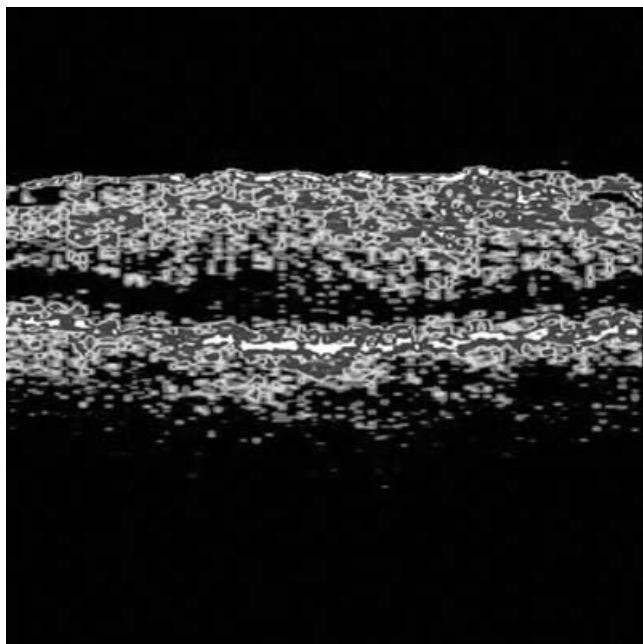


Figure 6. Standard picture for T1: presence of a continuous line of flat hyper-reflectivity adherent to the retina without significant retinal distortion, associated to edema type E1 (Simple Retinal Thickening).

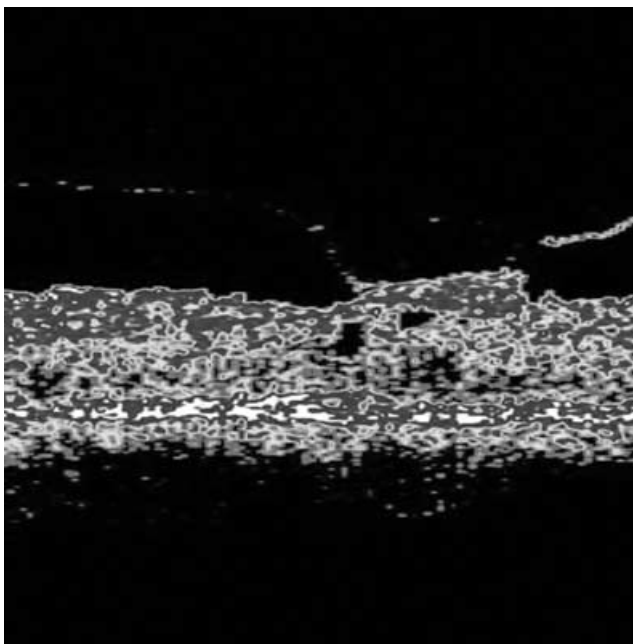


Figure 8. Standard Fig. T3. Antero-posterior traction with "gull wings" configuration, associated with mild cystoid macular edema E2a.

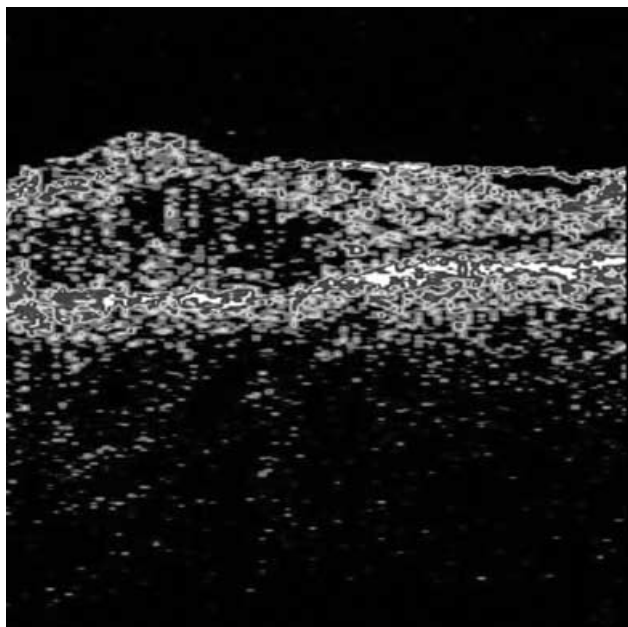


Figure 7. Standard picture for T2. Presence of continuous line of hyper-reflectivity with multiple points of adhesion to the retina and with significant retinal distortion, associated with Simple macular Thickening E1.

The reliability of OCT measurements of retinal thickness has been proven by histologic studies,^{2,3} and the accuracy and intra/interobserver reproducibility of OCT measurements of retinal thickness have been tested and confirmed by many authors.^{4,5,6-8,9,10}

OCT has been demonstrated to be more sensitive than biomicroscopy not only to detect small changes in retinal thickness,^{9,11,12,13} but also in cases of cystoid edema¹⁴ and in identifying vitreoretinal adhesions associated with macular disease.¹⁵ Furthermore, the presence of retinopathy seems to favor false-positive readings of macular edema in a clinical setting.¹⁶

The accuracy of measurements has been greatly enhanced by the new version of the software by means of increased density of measurements (512 points for a 6 mm scan).

Moreover, the topographic mapping protocol provides geographic information on macular thickness that has been characterized as intuitive and objective.¹

The retinal thickness measured by OCT is not influenced by age,¹³ refractive error,¹⁷ left or right eye.^{1,13} Although a minimal difference was found in foveal thickness between men and women,¹³ this difference is not clinically relevant.

The normal macular thickness in healthy subjects has been tested with OCT by many authors.^{1,8,9,11,13,18,19} All measurements report similar values.

The normal retinal thickness at the fixation point can be considered 150 microns \pm 20, and the average foveal thickness in an area of 1000 microns in diameter is 170 \pm 20 microns.

The normal retinal thickness in perifoveal and peripheral areas has also been measured.^{12,13} Although minimal differences are present among the areas, especially at the horizontal raphe, we can consider a general clinical normal value of 230 ± 20 microns.

No differences have been found in retinal thickness between normal subjects and diabetic patients without evidence of diabetic retinopathy,^{1,13} but in isolated cases OCT found an abnormal retinal thickening in apparently “normal” diabetic eyes,^{1,13,20} suggesting therefore that close follow up is indicated for these eyes that may develop clinically significant macular edema.

Considering these results, to maintain a “clinical value” to the definition of retinal thickening, for each zone (fixation, central, and periphery) we distinguished in our classification three levels of thickness: normal value, borderline value of doubled standard deviation and clinically relevant thickening. The amplitude of the borderline zone is anyway arbitrary, and this classification cannot be considered as a treatment flow chart. The decision about therapy will obviously depend on the clinical judgment of the observer and will be also related to intraretinal morphology, and/or anomalous vitreoretinal relationships.

Regarding volume, there is no literature on normal or pathologic values, and the numbers reported in this classification are the result of our personal experience. This measure is not particularly relevant in its absolute values, but can be useful in the follow up of macular edema in cases of diffuse thickening: in these cases a stable measurement at fixation point or at central zone can be associated with significant changes in total volume, suggesting a global worsening not otherwise detectable.

Regarding morphology, a distinction among different patterns of macular edema and progressive stages of cystoid changes is in our opinion fundamental for a complete classification and also essential for a correct evaluation of different therapeutic strategies.

Although many authors used OCT in the diagnosis and treatment of macular edema focusing on retinal thickness values, to our knowledge only Otani in 1999¹⁹ and then us in 2003²¹ distinguished three patterns of morphology visible at OCT, adding to the clinically well known categories of simple macular thickening (Fig. 1) and cystoid edema (Figs. 2–3) a third pattern of fluid deposit under the neurosensory retina that is usually found in combination with large cystoid spaces (Fig. 4b), but that can also be rarely found isolated (Fig. 4a). Although this neuroepithelial detachment is not formally a form of macular edema defined as retinal thickening, we agree with Otani in considering this accumulation of fluid as a third form of edema only visible with OCT and that in our experience can be considered as a sign of long-standing fluid deposit when associated with cystoid changes.

In this classification, we identify three patterns of cystoid edema, from the first clearly visible presence of minimal cystoid spaces to the typical petaloid pattern and finally to the coalescence of cystoid spaces into large cavities of

retinoschisis. In our experience, this last pattern is associated with a moderate retinal thickening (less than the other morphologies) and a profound visual loss, and probably represents the last stage of retinal disruption.

About the presence of epiretinal traction, the distinction between the normal reflectance of the internal retinal surface and the hyper-reflectivity generated by an epiretinal membrane is not always clearly interpretable at OCT without the help of direct fundus examination. Moreover, it is rarely (if ever) possible with OCT to distinguish an epiretinal membrane from a contracted internal limiting membrane or an adherent posterior hyaloid based on grade of hyper-reflectivity. Only the presence of antero-posterior focal traction is an indicator of incomplete vitreo-retinal separation. In this classification we therefore do not speculate about the cause of epiretinal traction, but we only describe its morphology (tangential or antero-posterior) and differentiate a flat membrane adherent to the retina (Fig. 6) from a contracted membrane generating retinal distortion (Fig. 7). This parameter will then be evaluated in combination with retinal thickness and morphology.

In conclusion, this classification organizes all the data on macular edema generated by OCT to obtain the maximal information about the severity of retinal swelling, its morphology and the presence of epiretinal traction.

Although to determine the correct treatment for macular edema the OCT test and this classification cannot substitute a direct examination of the macular area and a vascular evaluation by fluorescein angiography, a complete and precise definition of macular edema in all its multiple components is fundamental for a correct interpretation of every therapeutic strategy.

Bibliography

1. Hee MR, Puliafito CA, Duker JS *et al.* Topography of diabetic macular edema with optical coherence tomography. *Ophthalmology*. 1998;105:360–370.
2. Chauhan DS, Marshall J. The interpretation of optical coherence tomography images of the retina. *Invest Ophthalmol Vis Sci*. 1999;40:2332–2342.
3. Ge J, Luo R, Guo Y. Corrective change of retinal thickness measured by optical coherence tomography and histologic studies. *Yan Ke Xue Bao*. 1999;15:153–155, 178.
4. Muscat S, Parks S, Kemp E, Keating D. Repeatability and reproducibility of macular thickness measurements with the Humphrey OCT system. *Invest Ophthalmol Vis Sci*. 2002;43:490–495.
5. Goebel W, Kretzchmar-Gross T. Retinal thickness in diabetic retinopathy: a study using optical coherence tomography (OCT). *Retina*. 2002;22:759–767.
6. Alamouti B, Funk J. Retinal thickness decreases with age: an OCT study. *Br J Ophthalmol*. 2003;87:899–901.
7. Strom C, Sander B, Larsen N, Larsen M, Lund-Andersen H. Diabetic macular edema assessed with optical coherence

- tomography and stereo fundus photography. *Invest Ophthalmol Vis Sci.* 2002;43:241–245.
8. Konno S, Akiba J, Yoshida A. Retinal thickness measurements with optical coherence tomography and the scanning retinal thickness analyzer. *Retina.* 2001;21:57–61.
 9. Massin P, Vicaud E, Haouchine B, Erginay A, Paques M, Gaudric A. Reproducibility of retinal mapping using optical coherence tomography. *Arch Ophthalmol.* 2001;119:1135–1142.
 10. Koozekanani D, Roberts C, Katz SE, Herderick EE. Inter-session repeatability of macular thickness measurements with the Humphrey 2000 OCT. *Invest Ophthalmol Vis Sci.* 2000;41:1486–1491.
 11. Hee MR, Puliafito CA, Wong C *et al.* Quantitative assessment of macular edema with optical coherence tomography. *Arch Ophthalmol.* 1995;113:1019–1029.
 12. Schaudig UH, Glaefke C, Scholz F, Richard G. Optical coherence tomography for retinal thickness measurement in diabetic patients without clinically significant macular edema. *Ophthalmic Surg Lasers.* 2000;31:182–186.
 13. Massin P, Erginay A, Haouchine B, Mehidi AB, Paques M, Gaudric A. Retinal thickness in healthy and diabetic subjects measured using optical coherence tomography mapping software. *Eur J Ophthalmol.* 2002;12:102–108.
 14. Yang CS, Cheng CY, Lee FL, Hsu WM, Liu JH. Quantitative assessment of retinal thickness in diabetic patients with and without clinically significant macular edema using optical coherence tomography. *Acta Ophthalmol Scand.* 2001;79:266–270.
 15. Gallemore RP, Jumper JM, McCuen BW, 2nd, Jaffe GJ, Postel EA, Toth CA. Diagnosis of vitreoretinal adhesions in macular disease with optical coherence tomography. *Retina.* 2000;20:115–120.
 16. Yang Y, Vitale S, Ding Y *et al.* A comparison of quantitative mapping and stereoscopic fundus photography grading of retinal thickness in diabetic eyes with macular edema. *Ophthalmic Surg Lasers Imaging.* 2003;34:7–16.
 17. Wakitani Y, Sasoh M, Sugimoto M, Ito Y, Ido M, Uji Y. Macular thickness measurements in healthy subjects with different axial lengths using optical coherence tomography. *Retina.* 2003;23:177–182.
 18. Baumann M, Gentile RC, Liebmann JM, Ritch R. Reproducibility of retinal thickness measurements in normal eyes using optical coherence tomography. *Ophthalmic Surg Lasers.* 1998;29:280–285.
 19. Otani T, Kishi S, Maruyama Y. Patterns of diabetic macular edema with optical coherence tomography. *Am J Ophthalmol.* 1999;127:688–693.
 20. Sanchez-Tocino H, Alvarez-Vidal A, Maldonado MJ, Moreno-Montanes J, Garcia-Layana A. Retinal thickness study with optical coherence tomography in patients with diabetes. *Invest Ophthalmol Vis Sci.* 2002;43:1588–1594.
 21. Panozzo G, Gusson E, Parolini B, Mercanti A. Role of OCT in the diagnosis and follow up of diabetic macular edema. *Semin Ophthalmol.* 2003;18:74–81.