

RWC RETINA ROCKS IMAGE GALLERY CASE OF THE MONTH

Choroidal Hemangioma Widefield Optical Coherence Tomography

Submitted by: Barbara Parolini, MD; Veronika Matello; Eyecare Clinic, Brescia, Italy

A healthy 45-year-old woman was referred for macular schisis in the left eye. Visual acuity was 20/50. Color photography showed an orange-red subretinal lesion nasal to the nerve (**Figure 1**, top). Widefield optical coherence tomography (OCT) image showed an elevated hyporeflective choroidal mass with overlying cystic retinal edema (**Figure 1**, bottom, yellow arrow). Subfoveal fluid (orange arrow) with cystic fluid in the outer retina (pink arrow) was noted in the macula. An en face OCT of the outer retina better visualized the cystic changes (**Figure 2**). The choroidal lesion with overlying retinal edema significantly improved following photodynamic therapy (**Figure 3**). Visual acuity also improved to 20/20.

Widefield imaging is revolutionizing the way retinal disease is diagnosed and treated. This case is a perfect example where macular imaging alone could point to an incorrect diagnosis. In this case, the macular findings in isolation suggested either optic pit maculopathy¹ or paraproteinemic maculopathy.² Widefield OCT technology led to a correct diagnosis, allowing for appropriate treatment with excellent anatomic and visual results.

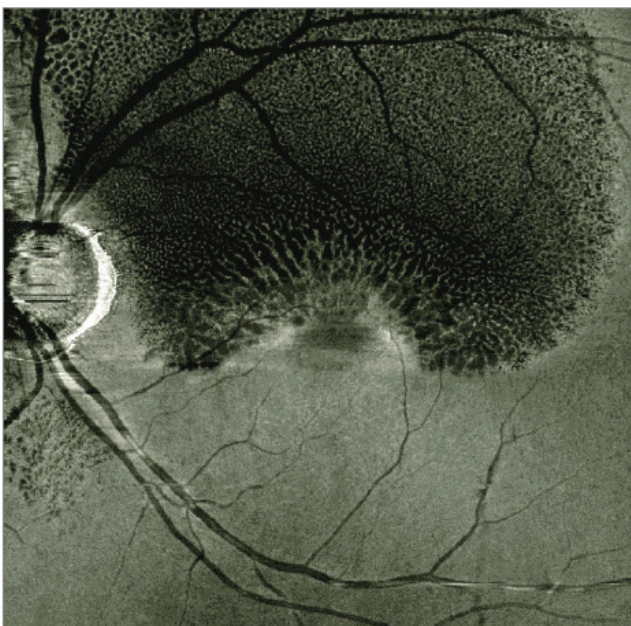


Figure 2. En face OCT of the outer retina shows diffuse cystic changes.

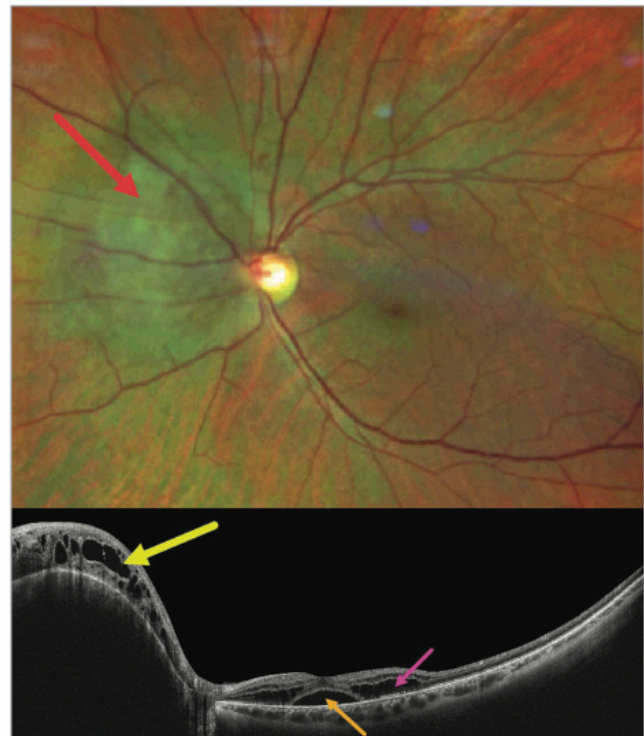


Figure 1. Optos imaging (top) of a choroidal hemangioma (red arrow). Widefield OCT through the hemangioma (bottom) shows an elevated hyporeflective choroidal mass with overlying cystic retinal edema (yellow arrow). Subfoveal fluid (orange arrow) with cystic fluid in noted in the outer retina (pink arrow).

REFERENCES

1. Imamura Y, Zweifel SA, Fujiwara T, Freund KB, Spaide RF. High-resolution optical coherence tomography findings in optic pit maculopathy. *Retina*. 2010;30(7):1104-1112. <https://doi.org/10.1097/LAE.0b013e3181d87ecb> PMID:20523264
2. Mansour AM, Arevalo JF, Badal J, et al. Paraproteinemic maculopathy. *Ophthalmology*. 2014;121(10):1925-1932. <https://doi.org/10.1016/j.ophtha.2014.04.007> PMID:24950591

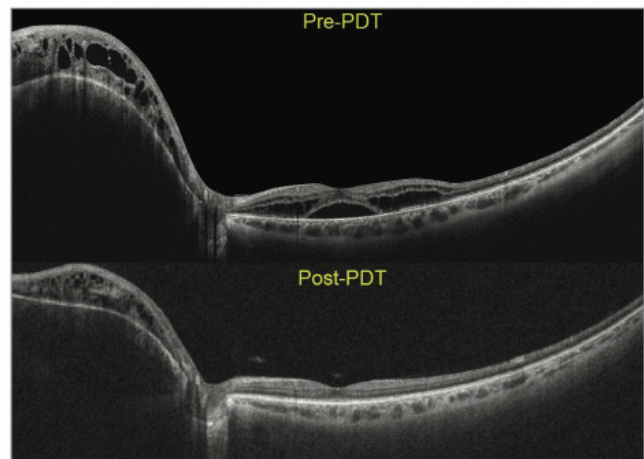


Figure 3. The choroidal lesion with overlying retinal edema significantly improved following photodynamic therapy.