

INDICATIONS AND RESULTS OF A NEW L-SHAPED MACULAR BUCKLE TO SUPPORT A POSTERIOR STAPHYLOMA IN HIGH MYOPIA

BARBARA PAROLINI, MD,* RINO FRISINA, MD,* SAJISH PINACKATT, MD,*
ROBERTO GASPAROTTI, MD,† ENZA GATTI, MD,† ANDREA BALDI, MD,‡ ROBERTA PENZANI, OD,*
ANGELA LUCENTE, OD,* FRANCESCO SEMERARO, MD‡

Background: The efficacy of a macular buckle in treating myopic traction maculopathy was studied.

Methods: Fifty eyes with myopic traction maculopathy, in the form of macular detachment with macular hole (MHMD), or without macular hole (MD) and macular foveoschisis (MF), were treated with vitrectomy combined with macular buckle or with a macular buckle without vitrectomy.

Results: *Combined group:* The combined group comprised 10 eyes with MHMD, 6 eyes with MD, and 4 eyes with MF. The retina was attached in 100% of MD and MHMD and the MF was improved in 100% of cases. The hole was closed in 60% of MHMD. The mean initial and final Snellen best-corrected visual acuity was 20/500 and 20/100 for MHMD, 20/200 and 20/60 for MD, and 20/200 and 20/50 for MF. The mean surgical time was 80 ± 35 minutes. Fundus angiography or indocyanine green revealed no alteration of the chorioretinal blood flow. Buckle shortening was required in 6/20 (30% of cases) patients for lateral extrusion of the sponge through the conjunctiva with the first sponge model. This complication was overcome by changing the arm of the buckle. *Buckle group:* The buckle group comprised 5 eyes with MHMD, 11 with MD, and 14 with MF. The retina was attached in 100% of MHMD, MD, and MF. The macular hole was closed in 60%. The mean initial and final Snellen best-corrected visual acuity was 20/800 and 20/60 for MHMD, 20/125 and 20/50 for MD, and 20/200 and 20/63 for MF. The mean postoperative decrement in axial length was 1.21 mm. The mean surgical time was 35 ± 15 minutes. Fundus angiography or indocyanine green revealed no alteration of the chorioretinal blood flow. Complications included conjunctiva erosion (15%), diplopia (7.7%), and pain (3.8%). Magnetic resonance imaging showed flattening of the posterior staphyloma.

Conclusion: Considering the possible complications and technical difficulties of vitrectomy, we suggest that the macular buckle alone should be the first treatment of myopic traction maculopathy. Vitrectomy should be reserved only for cases of tangential tractions.

RETINA 35:2469–2482, 2015

Macular foveoschisis (MF), macular detachment without macular hole (MD), and macular detachment with macular hole (MHMD), in a highly myopic eye, could be different stages of a progressive

From the *Department of Ophthalmology, S. Anna Hospital, Brescia, Italy; and Departments of †Radiology, and ‡Ophthalmology, University of Brescia, Brescia, Italy.

None of the authors have any financial/conflicting interests to disclose.

Reprint requests: Barbara Parolini, MD, Istituto Clinico S. Anna, Via del Franzone 31, Brescia 25127, Italy; e-mail: parolinibarbara@gmail.com

disease well described as myopic traction maculopathy (MTM),¹⁻³ associated with a posterior staphyloma.

The pathogenesis and natural history of MTM are still uncertain, and the best management is debated.⁴ Elimination of epiretinal tractions by means of vitrectomy with or without internal limiting membrane (ILM) peeling seems an acceptable approach and has proven to be effective.⁵⁻⁸ Vitrectomy alone, however, causes a transient release of the traction⁹ without addressing the major risk factor of the MTM, which is

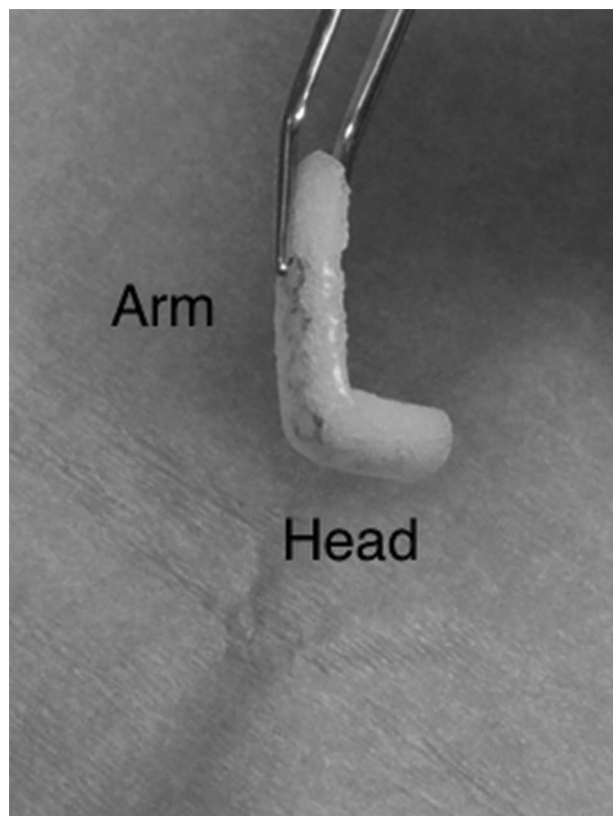


Fig. 1. An L-shaped macular buckle. A titanium stent is inserted into a silicone sponge. The buckle is bent in the shape of an L, with a short side (the head of the buckle) to indent the macula and a long side (the arm of the buckle) to be placed parallel to the lateral rectus muscle. The arm of the buckle is thinned.

the posterior staphyloma.¹ Furthermore, it should be noted that vitrectomy with ILM peeling, in highly myopic eyes, may lead to complications, such as macular hole (MH) formation or extrafoveal retinal hole formation.⁸ Vitrectomy to treat MHMD is also associated with a high recurrence rate of the retinal detachment,

which makes this surgical strategy still not completely successful.¹⁰

To give a new shape to the posterior scleral wall and to reduce the tractions secondary to the staphyloma, the use of a scleral buckle has been previously reported, with good anatomical and functional results.^{11–13}

The authors of this article believe that an L-shaped buckle design¹⁴ is the easiest to place and leads to the lowest risk of intraoperative and postoperative complications.

This study on patients with MTM has 3 purposes: 1) to test long-term tolerability and safety of an L-shaped buckle, which can be tailored in the operating room, 2) to report a 3 years of follow-up in a group of patients treated with combined vitrectomy and an L-shaped macular buckle, which were followed retrospectively, and 3) to report a prospective follow-up of a group of patients treated with the L-shaped macular buckle alone, with the aim of clarifying whether the application of an L-shaped macular buckle could obtain at least comparable main and secondary outcomes, with an easier, safer, and faster surgery.

Methods

A thorough informed consent was obtained from the patients. One surgeon (B.P.) operated every eye.

Combined Group

The authors retrospectively examined the charts of 20 eyes of 20 patients, with original refraction equal or higher than 6 diopters of spherical equivalent that were operated between January 2011 and January 2014, to evaluate complications of MTM. Data were available

Table 1. Data of the Eyes With MHMD, Operated With Combined Vitrectomy and Macular Buckle

Patient Code	Preop Axial Length	Postop Axial Length	Lens Status Preop PH, PS	BCVA Pre (Snellen)	Final BCVA (Snellen)	Retinal Attachment	Hole Closure	Postoperative Complications
1MHMD	30.01	27.27	PH	20/2,000	20/100	Yes	Yes	
2MHMD	33.84	30.63	PH	20/2,000	20/100	Yes	No	Lateral extrusion requiring buckle shortening
3MHMD	35.56	32.82	PS	20/200	20/100	Yes	Yes	
4MHMD	30.20	29.01	PS	20/400	20/200	Yes	No	
5MHMD	32.23	31.43	PS	20/2,000	20/200	Yes	Yes	
6MHMD	33.34	30.02	PH	20/2,000	20/200	Yes	Yes	
7MHMD			PH	20/2,000	20/200	Yes	Yes	
8MHMD	35.7	33.87	PH	20/2,000	20/200	Yes	No	
9MHMD			PH	20/200	20/25	Yes	Yes	
10MHMD	32.87	30.28	PH	20/2,000	20/250	Yes	No	

PH, phakic; PS, pseudophakic.

BCVA change in eyes operated with combined surgery for MHMD

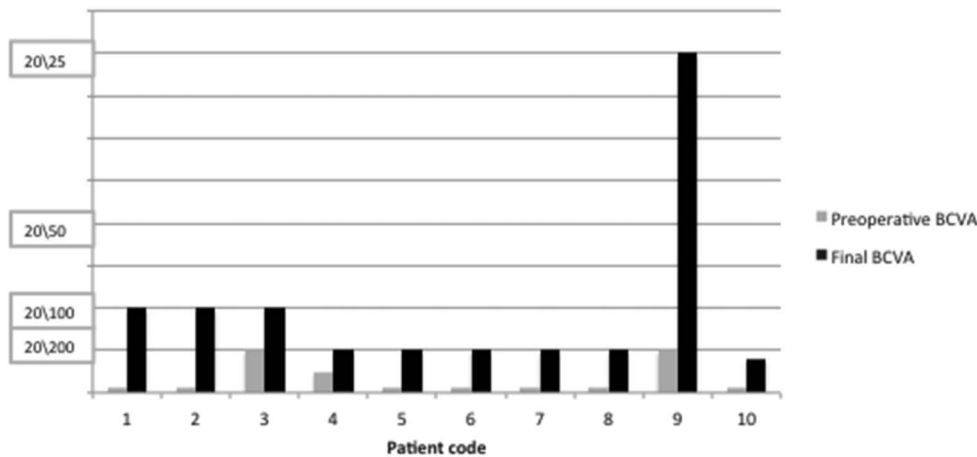


Fig. 2. The graph shows the BCVA change in each eye operated with combined vitrectomy and macular buckle for MHMD.

until 3 years of follow-up for some eyes. This group comprised 10 eyes with MHMD, 6 eyes with MD, and 4 eyes with MF. This study group will subsequently be referred to as the “combined group.” Eyes with previous surgery and with other ophthalmic pathologies other than MTM were excluded from the study.

The eyes in the combined group received 20-gauge extensive pars plana vitrectomy. The posterior hyaloid was always firmly attached to the retina and was removed with a bimanual technique with forceps in one hand and a back-flush needle in the other hand, after staining multiple times with triamcinolone acetate. The back-flush needle was used to elevate and aspirate the posterior vitreous cortex and the triamcinolone remnants, whereas the forceps were used to peel the posterior cortex. The ILM peeling was assisted with brilliant blue G staining. A macular buckle was inserted in the superotemporal quadrant, with the lateral arm parallel to the lateral rectus muscle and sutured anteriorly to the sclera, 1 mm to 2 mm

posterior to the insertion of the lateral rectus muscle. As endotamponade, SF6 gas was used for MHMD and air for MD and MF.

The main outcome of this study was the anatomical success defined as reattachment of the retina with resolution of the MTM in the macula with one operation. Secondary outcomes were the complete closure of the macular holes among the eyes with MHMD and the differential best-corrected visual acuity (BCVA) in Snellen.

Eyes in the combined group were evaluated preoperatively for BCVA, intraocular pressure (IOP), refraction, and spectral domain optical coherence tomography (Spectralis [Heidelberg Engineering, Heidelberg, Germany] or Optos [Dunfermline, United Kingdom]).

The eyes were evaluated postoperatively for BCVA, IOP, refraction, and OCT. Some patients were also examined with fundus angiography (FA) and indocyanine green (ICG).

Table 2. Data of the Eyes With Macular Detachment (MD), Operated With Combined Vitrectomy and Macular Buckle

Patient Code	Preop Axial Length	Postop Axial Length	Lens Status Preop PH, PS	BCVA Pre (Snellen)	Final BCVA (Snellen)	Retinal Attachment After Surgery	Hole Closure After Surgery	Postoperative Complications
1MD	29.21	27.92	PS	20/200	20/63	Yes	NA	
2MD	30.23	28.72	PS	20/200	20/63	Yes	NA	
3MD	28.42	27.65	PS	20/63	20/20	Yes	NA	Lateral extrusion requiring buckle shortening
4MD	27.14	26.15	PS	20/400	20/250	Yes	NA	
5MD			PH	20/2,000	20/400	Yes	NA	
6MD			PH	20/400	20/400	Yes	NA	

NA, not applicable; PH, phakic; PS, pseudophakic.

BCVA change in eyes operated with combined surgery, for MD

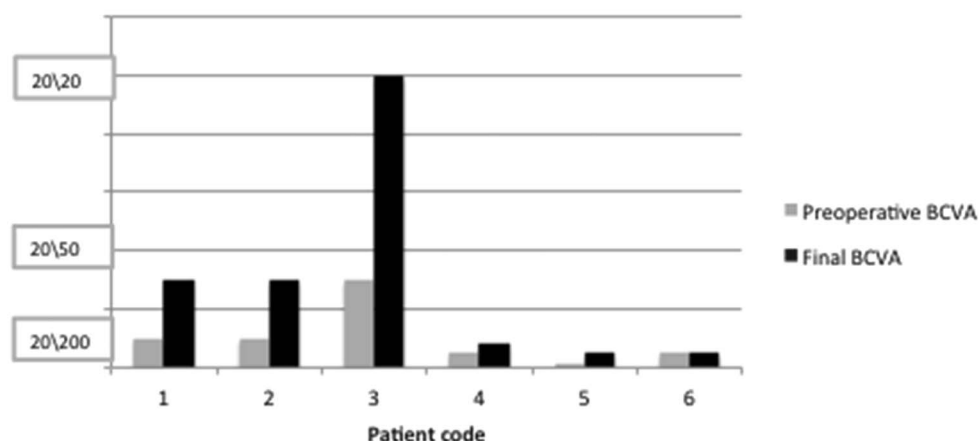


Fig. 3. The graph shows the BCVA change in each eye operated with combined vitrectomy and macular buckle for MD.

Buckle Group

The buckle group comprised 30 eyes of 29 patients, with axial length (AL) equal or longer than 26 mm and original refraction equal or higher than 6 D of spherical equivalent, affected by MTM, operated between June 2011 and April 2014. This group comprised 5 eyes with MHMD, 11 eyes with MD, and 14 eyes with MF. This study group will subsequently be referred to as the “buckle group.” Eyes with previous surgery and with other ophthalmic pathologies other than MTM were excluded from the study.

These eyes received only a macular buckle associated with a paracentesis in the anterior chamber, without vitrectomy and without internal maneuvers. The paracentesis allowed a better indentation of the buckle and a better intraoperative control of the IOP. The patients operated for MHMD received also an intravitreal injection of 0.3 cc of SF6 and were asked to maintain the facedown positioning for 3 days. MD and MF did not receive any tamponade and were not asked to maintain any position.

In the buckle group, the same preoperative data were collected as in the combined group along with evaluations of AL, magnetic resonance imaging (MRI), and clinical examination. In this group, the height of the MD and of the MF was measured in the highest point with spectral domain optical coherence tomography. Patients with MD and MF also underwent FA and ICG examination.

Magnetic resonance imaging was used to study the 3D reconstruction of the globe and the external shape of the staphyloma. The aim of MRI was the ability to make a comparison between the preoperative and the postoperative shape of the globe and to judge the relationship between the buckle and the optic nerve.

The fundus was classified using the classification published by Hsiang et al.¹⁵ The staphyloma was classified using the classification published by Curtin.¹⁶

Postoperatively, the eyes were examined to check BCVA, IOP, refraction, AL, FA, ICG, and spectral domain optical coherence tomography scans at least at 1 week, 1 month, 3 months, and 6 months after surgery. The postoperative spectral domain optical coherence tomography scans were aligned with the

Table 3. Data of the Eyes With MF Operated With Combined Vitrectomy and Macular Buckle

Patient Code	Preop Axial Length	Postop Axial Length	Lens Status Preop PH, PS	BCVA Pre (Snellen)	Final BCVA (Snellen)	Retinal Attachment	Hole Closure	Postoperative Complications
1MF	27.23	26.52	PH	20/63	20/50	Yes	NA	Lateral extrusion requiring buckle shortening
2MF	28.10	27.51	PH	20/400	20/80	Yes	NA	
3MF	27.72	26.63	PH	20/63	20/32	Yes	NA	
4MF			PH	20/100	20/63	Yes	NA	

NA, not applicable; PH, phakic; PS, pseudophakic.

BCVA change in eyes operated with combined surgery for MF

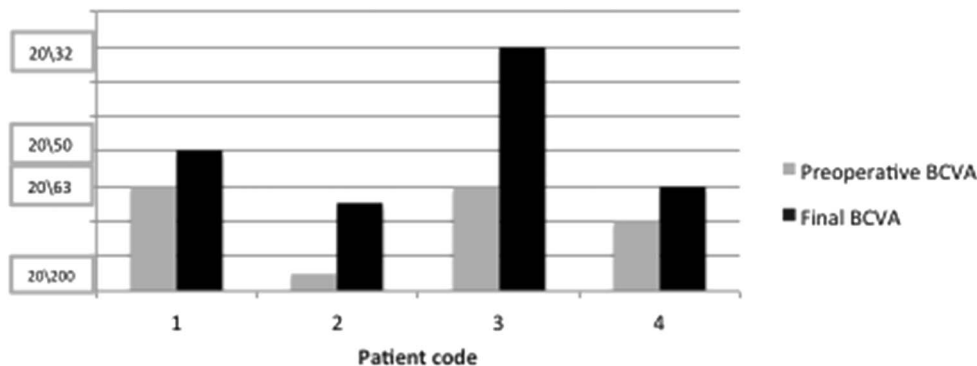


Fig. 4. The graph shows the BCVA change in each eye operated with combined vitrectomy and macular buckle for MF.

preoperative for comparative measurements. Magnetic resonance imaging and clinical examinations were performed once postoperatively.

The surgical technique related to the macular buckle is described elsewhere.¹⁴ In summary, the macular buckle was prepared using a silicone sponge (Labtician 507 oval sponge) 7 mm large, 5 mm thick, and 3 cm long. The sponge was thinned for a length of 2 cm to make the buckle more prominent in that one third intended to be placed under the macula (head of the buckle) and thin in the 2 remaining thirds (tail of the buckle) to allow suturing the buckle anteriorly. A tunnel was created into the silicone sponge with a 19-gauge needle. A malleable titanium stent (Mod MCP6TP; Tekka, Pesaro, Italy) 15 mm long, 2 mm wide, and 0.5 mm high was inserted and hidden into the tunnel. The sponge could then be bent to obtain an L-shaped buckle by creating a 90° angle between the head and the tail (Figure 1).

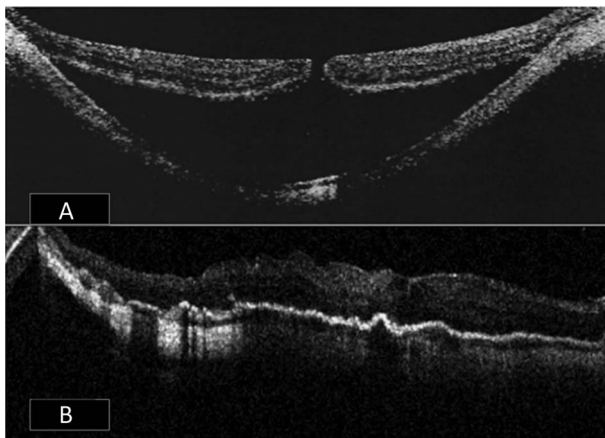


Fig. 5. A. Preoperative OCT of a high myopic eye with MHMD. B. OCT of the same myopic eye, 1 day after insertion of the macular buckle plus the injection of a bubble of 0.4 cc of SF₆ and facedown positioning (buckle group). The retina was attached and the macular hole was completely closed and not visible.

Recently (October 2013), the design of the buckle was slightly changed and the titanium stent, in the tail of the buckle, was covered with a solid silicone sleeve (Labtician 72). The silicone sponge was left to cover the titanium stent in the head of the buckle. The aim of the change in the design was to reduce the risk of conjunctival erosion induced by the silicone sponge in the arm of the buckle.

To ensure the exact intraoperative positioning of the buckle, the fundus was observed through a panoramic system (RUV, Leica) attached to the microscope and was illuminated with one of the 27-gauge twin-lights (DORC, Zuidland, the Netherlands) inserted through the sclera, 4 mm from the limbus. The other 27-gauge light fiber was inserted into the head of the buckle to transilluminate the fundus and to facilitate the check of the final position of the buckle. The buckle was slid, head down, into the superotemporal quadrant, aligned to the lateral rectus muscle and held by forceps until the head induced a good indentation of the macula, as observed through the RUV and with transillumination. The tail of the buckle was then fixed to the sclera with two 6 to 0 Ti-Cron mattress sutures placed about 1 mm to 2 mm from the insertion of the lateral rectus muscle.

Results

Combined Group

Eyes in the combined group had a follow-up between 3 months and 3 years.

Eyes Operated for Macular Detachment With Macular Hole

The retina was attached with one operation, since the first week after surgery, without signs of MTM, in

Table 4. Data of the Eyes With MHMD Operated With Macular Buckle Alone

Patient Code	Fundus Classification*	Staphyloma Classification†	Preop Axial Length, mm	Postop Axial Length, mm	Lens Status Preop PH, PS	BCVA Pre (Snellen)	Final BCVA (Snellen)	Preop Foveal Thickness, μm	Post Foveal Thickness, μm	Retinal Attachment	Hole Closure	Postoperative Complications
CV	M4	IX	30.01	29.90		20/2,000	20/25	NA	NA	Yes	Yes	
RE	M4	IX	31.02	29.72		20/2,000	20/400	NA	NA	Yes	No	
AM	M4	VII	30.98	28.92		20/2,000	20/63	NA	NA	Yes	Yes	Optic nerve kinking 2 months after surgery and retinal hemorrhages resolved with buckle removal
VG	M4	VII	29.09	28.76		20/400	20/50	NA	NA	Yes	Yes	
MI	M5	IX	31.02	29.04		20/2,000	20/400	NA	NA	Yes	No	

*By Hsiang et al.¹⁵

†By Curtin.¹⁶

PH, phakic; PS, pseudophakic.

every eye, and remained attached for the whole length of the follow-up (Table 1). The macular hole was successfully closed in 6 of the 10 (60%) eyes.

The mean initial Snellen BCVA was 20/500. The mean final Snellen BCVA was 20/100. The difference was statistically significant ($P = 0.02$). The change in BCVA of each patient is shown in Figure 2. The mean surgical time was 80 ± 35 minutes. In 1 eye, the silicone sponge of the buckle was exposed in the temporal quadrant 1.5 months postoperatively and required surgery to shorten the lateral arm of the buckle.

Eyes Operated for MD

The macular detachment improved with 1 operation, since the first week after surgery, in every eye and progressively completely attached during the first month after surgery (Table 2). The macula remained attached for the whole length of the follow-up.

The mean initial Snellen BCVA was 20/200. The mean final Snellen BCVA was 20/60. The difference was statistically significant ($P = 0.06$). The change in BCVA of each patient is shown in Figure 3. The mean surgical time was 60 ± 15 minutes. No macular holes were iatrogenically induced. In 1 eye, the silicone sponge of the buckle was exposed in the temporal quadrant, 2 months after surgery, and required surgery to shorten the lateral arm of the buckle.

Eyes Operated for Macular Foveoschisis

The macular schisis improved with one operation, since the first week after surgery, in every eye and progressively completely resolved during the first month after surgery (Table 3). The macula remained attached for the whole length of the follow-up.

The mean initial Snellen BCVA was 20/200. The mean final Snellen BCVA was 20/50. The difference is statistically significant ($P = 0.03$). The change in BCVA of each patient is shown in Figure 4. The mean surgical time was 60 ± 15 minutes. No macular holes were iatrogenic ally induced.

In the combined group, 3 eyes (11%) had a stable increase in IOP and needed glaucoma medications. None of the eyes revealed alteration of the chorioretinal blood flow, either on FA or ICG examination. None of the eyes lost visual acuity postoperatively.

Buckle Group

Eyes in the buckle group had a follow-up between 3 months and 3 years.

BCVA change in eyes operated with buckle alone, for MDMD

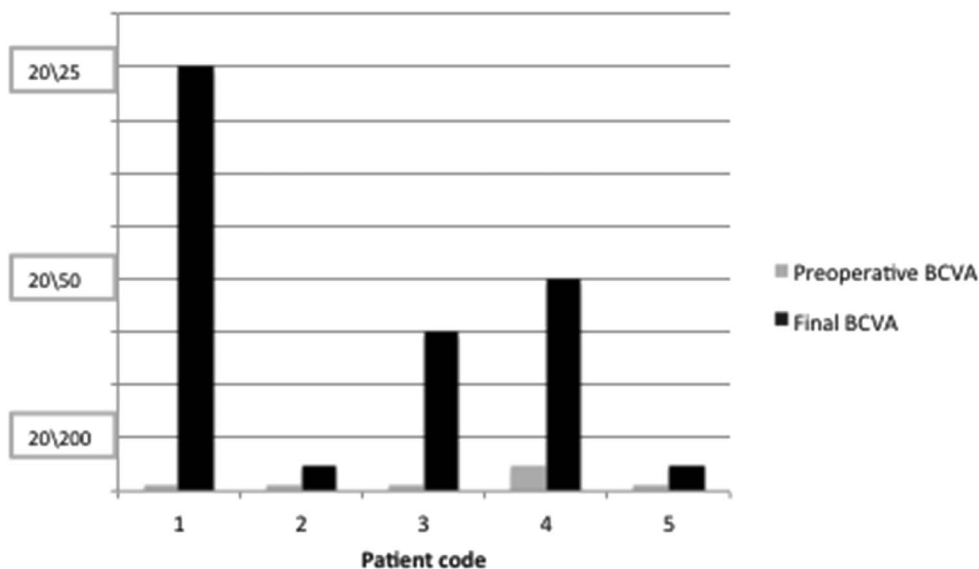


Fig. 6. The graph shows the BCVA change in each eye operated with the macular buckle alone for MHMD.

Eyes Operated for Macular Detachment With Macular Hole

The retina of the 5 eyes with MHMD (Figure 5A), operated with macular buckle, gas injection, and face-down positioning, was attached since the day after surgery (Figure 5B) and remained stable during the follow-up (Table 4). The macular hole was completely closed in 3 of the 5 eyes with MHMD (60%).

The mean preoperative Snellen BCVA was 20/800. The mean postoperative Snellen BCVA

was 20/60. The difference is statistically significant ($P = 0.05$). The change in BCVA of each patient is shown in Figure 6.

Reliable measurements of retinal detachment heights were difficult to collect at OCT because of the high distance between the retinal pigment epithelium and the ellipsoid zone, which was higher than $900 \mu\text{m}$ in every eye. The mean postoperative foveal thickness was $150 \pm 99 \mu\text{m}$. None of the patients revealed motility alteration or diplopia postoperatively. Magnetic resonance imaging was performed 1 month to 3 months postoperatively.

One eye showed intraretinal hemorrhages in the temporal peripheral retina 2 months after surgery. Magnetic resonance imaging showed optic nerve kinking in this patient. Therefore, the buckle was removed and the retina remained attached with disappearance of intraretinal hemorrhages.

The mean preoperative AL was $30.42 \pm 0.86 \text{ mm}$. The mean postoperative AL was $29.27 \pm 0.51 \text{ mm}$. The difference was statistically significant ($P = 0.02$). The mean change in AL was 1.15 mm. The mean refraction change was $2.0 \pm 0.5 \text{ D}$. The mean surgical time was $35 \pm 15 \text{ minutes}$.

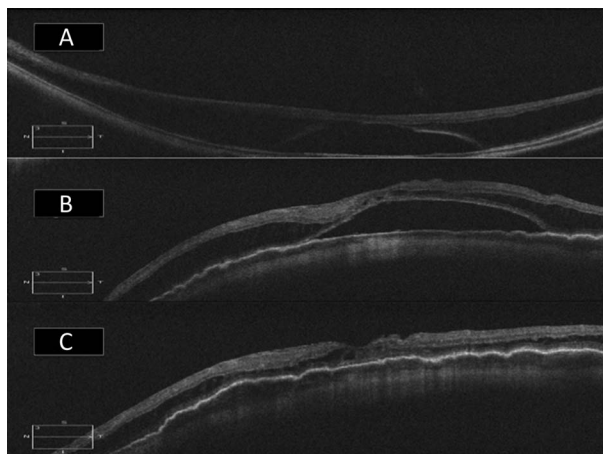


Fig. 7. A. Preoperative OCT of a high myopic eye, with macular detachment on the posterior staphyloma without macular hole. B. OCT of the same eye, 1 week after insertion of a macular buckle (buckle group). The macular detachment is only partially reabsorbed. C. OCT of the same eye, 6 weeks after insertion of the macular buckle. The macular detachment is completely resolved.

Eyes Operated for MD

The 11 eyes with MD (Figure 7A) showed a progressive decrease in the height of the macular detachment (Figure 7B) and release of anteroposterior tractions at OCT during the follow-up, reaching

Table 5. Data of the Eyes With Macular Detachment (MD) Operated With Macular Buckle Alone

Patient Code	Fundus Classification*	Staphyloma Classification†	Preop Axial Length, mm	Postop Axial Length, mm	Lens Status Preop PH, PS	BCVA Pre (Snellen)	Final BCVA (Snellen)	Preop Foveal Thickness, μm	Post Foveal Thickness, μm	Retinal Attachment	Hole Closure	Postoperative Complications
RC	M3	V	27.80	26.20	PH	20/100	20/40	600	140	Yes	NA	Early decentration resolved with recentration
CMP	M5	IX	27.90	26.65	PS	20/2,000	20/2,000	650	60	Yes	NA	
MS	M3	II	27.87	27.49	PH	20/50	20/50	590	205	Yes	NA	
ZD	M4	IV	32.08	31.20	PH	20/2,000	20/32	1,300		Yes	NA	
CM	M4	VII	29.90	27.70	PH	20/100	20/50	880	150	Yes	NA	Early decentration resolved with recentration
CG	M3-M4	II	32.14	30.10	PH	20/63	20/25	570	190	Yes	NA	
BB	M3	V	28.78	27.20	PH	20/200	20/100	555	680	Yes	NA	Pain and diplopia resolved with buckle removal
PT	M3	IX	30.10	28.90	PS	20/63	20/50	1,700	300	Yes	NA	Lateral extrusion requiring buckle shortening
AG	M3	II	30.21	29.03	PH	20/200	20/40			Yes	NA	
PC	M5	IX	32.10	30.50	PS	20/400	20/100	390	120	Yes	NA	
RA	M3-M4		30.01	29.05	PH	20/200	20/63			Yes	NA	

*By Hsiang et al.¹⁵†By Curtin.¹⁶

NA, not applicable; PH, phakic; PS, pseudophakic.

BCVA change in eyes operated with buckle alone, for MD

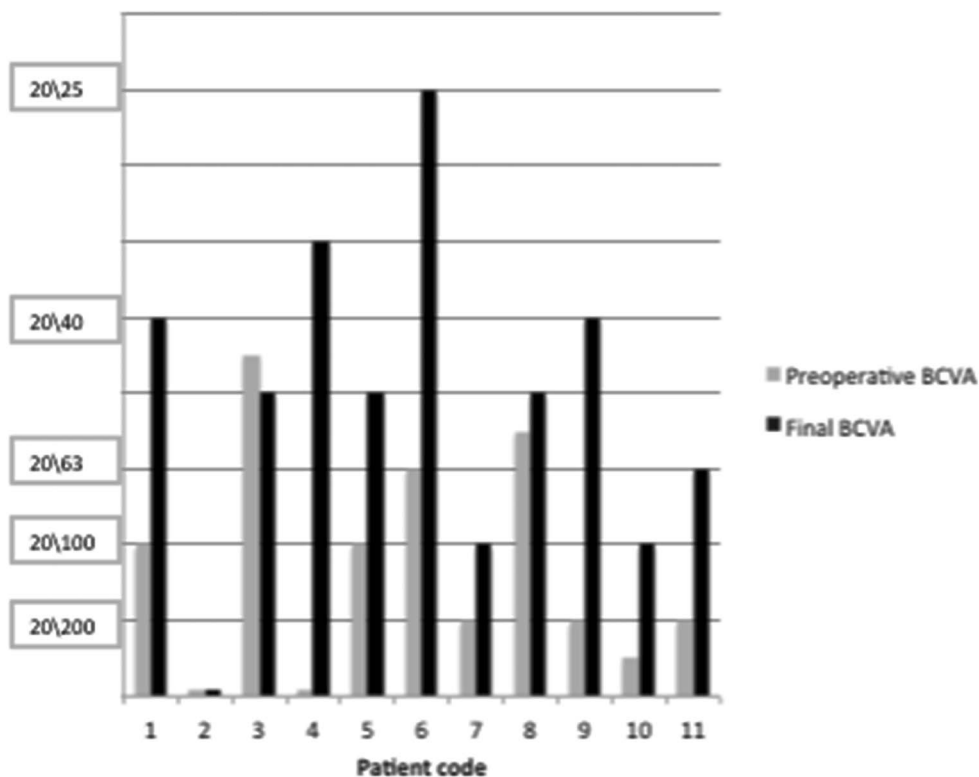


Fig. 8. The graph shows the BCVA change in each eye operated with a macular buckle alone for MD.

complete resolution within the third month visit (Figure 7C) (Table 5). In 3 patients (27%), it was necessary to reposition the buckle for improper centration in the early postoperative time (1–3 days postoperatively).

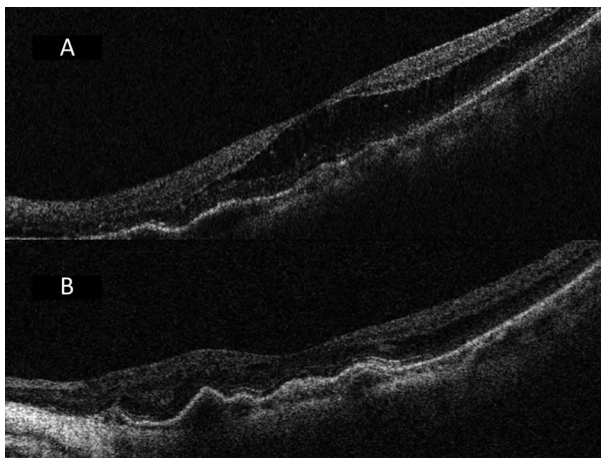


Fig. 9. **A.** Preoperative OCT of a high myopic eye with macular schisis on the posterior staphyloma without macular hole. **B.** OCT of the same eye, 8 weeks after insertion of a macular buckle (buckle group). The macular schisis is completely resolved. The macula, choroid, and sclera are flattened on the buckle.

The mean preoperative Snellen BCVA was 20/125. The mean postoperative Snellen BCVA was 20/50. The difference is statistically significant ($P = 0.003$). The change in BCVA of each patient is shown in Figure 8.

The mean preoperative height of the detachment was $803 \pm 426 \mu\text{m}$. The mean postoperative foveal thickness was $230 \pm 194 \mu\text{m}$. One patient (9%) had diplopia that required removing the buckle 2 weeks after surgery and 2 eyes presented lateral exposure of the arm of the buckle and required surgery to shorten the buckle.

The mean preoperative AL was $29.9 \pm 1.69 \text{ mm}$. The mean postoperative AL was $28.55 \pm 1.63 \text{ mm}$. The difference was statistically significant ($P = 0.04$). The mean change in AL was 1.35 mm. The mean refraction change was $2.25 \pm 0.5 \text{ D}$. The mean surgical time was $35 \pm 15 \text{ minutes}$.

Eyes Operated for Macular Foveoschisis

The 14 eyes with MF (Figures 9A and 10A) showed a progressive decrease in the height of the macular schisis at OCT during the follow-up reaching resolution within the third month (Figures 9B and 10B)

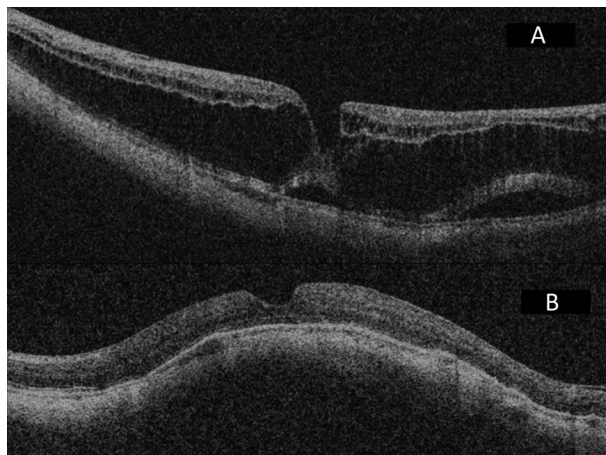


Fig. 10. A. Preoperative OCT of a high myopic eye with combined macular schisis and macular detachment on the posterior staphyloma without macular hole. B. OCT of the same eye, 12 weeks after insertion of a macular buckle (buckle group). The macular schisis and detachment are completely resolved. The macula, choroid, and sclera are flattened on the buckle.

(Table 6). A second operation was needed to reposition the buckle in 1 of the 14 (7%).

The mean preoperative Snellen BCVA was 20/200. The mean postoperative Snellen BCVA was 20/63. The difference was statistically significant ($P = 0.004$). The change in BCVA of each patient is shown in Figure 11.

The mean preoperative foveal thickness was $337 \pm 255 \mu\text{m}$. The mean postoperative foveal thickness was $255 \pm 151 \mu\text{m}$. One patient complained of temporary diplopia and another complained of pain and required buckle removal (7%).

The mean preoperative AL was $29.92 \pm 2.01 \text{ mm}$. The mean postoperative AL was $28.71 \pm 1.96 \text{ mm}$. The difference was statistically significant ($P = 0.0002$). The mean change in AL was 1.21 mm. The mean refraction change was $2.25 \pm 0.5 \text{ D}$. The mean surgical time was $35 \pm 15 \text{ minutes}$.

One eye required removal of the buckle for pain 2 days after surgery and in 1 eye the arm of the buckle was exposed 2 months after surgery and required shortening. None of the eyes revealed alteration of the chorioretinal blood flow either in FA or in ICG. None of the eyes lost visual acuity postoperatively.

Although the anteroposterior tractions was relieved with the buckle, 3 eyes presented residual tangential tractions (Figure 12A), which required vitrectomy and peeling of the vitreous cortex, epiretinal membrane, and ILM to restore the retinal anatomy (Figure 12B). No intraoperative complications were noted and the IOP remained normal during the follow-up in all eyes.

Postoperative MRI showed a flattening or a slight convex scleral shape in the location of the posterior staphyloma (Figure 13, A–D).

Additionally, on OCT, the most frequent change in the retino–choroidal–scleral profile induced by the macular buckle was not a convex shape with inversion of the staphyloma, but a flattening of the staphyloma (Figure 14, A and B).

Discussion

In this article, the efficacy and safety of an L-shaped macular buckle, in combination with pars plana vitrectomy and tamponade, but also as the first and only procedure to resolve MHMD, MD, and MF because of the posterior staphyloma are shown. As initial experience with the macular buckle, the surgeon decided to use it in combination with vitrectomy to treat cases of MTM. The promising anatomical results of the retrospective review of combined surgery gave the input to start a prospective study, with the aim to demonstrate the efficacy of the application of an L-shaped macular buckle alone in treating these diseases.

BCVA was a secondary outcome in both studies. The final visual function was not always indicative of surgical success as wide zones of myopic macular atrophy often precluded the visual gain. Visual field could have been more useful in observing a functional improvement, but it was not routinely performed in these eyes. Nevertheless, a clinically significant visual gain was noticed both in the combined group and in the buckle group for each form of MTM.

Many different buckling techniques have been proposed in the history of the surgery of MTM. They have been described mainly to treat cases of MHMD.^{17–21} It is the opinion of the authors that some buckle designs have been abandoned for three main reasons. First of all, the inability to check the exact position of the buckle intraoperatively, mainly because of the lack of high magnification panoramic view system and endoillumination. In the opinion of the authors, the use of indirect ophthalmoscopy implies more difficulties than looking through the microscope. The second reason was the technical difficulty in placing sutures posteriorly at the back of the macula. The third reason was the amount of complications at the posterior pole (subretinal hemorrhages) also linked to the technique that implied to suture the buckle at the back of the eye globe. Other authors^{22–25} have described the use of different designs of a buckle for MF and MD. Recently, a silicone C-shaped macular buckle with adjustable sutures has also been proposed by Stirpe et al²⁵ in a few cases, as a secondary procedure in cases of vitrectomy failure.

Our design of macular buckle may be safer and easier to place than previously described methods of episcleral macular buckling, because it does not

Table 6. Data of the Eyes With MF Operated With Macular Buckle Alone

Patient Code	Fundus Classification*	Staphyloma Classification†	Preop Axial Length, mm	Postop Axial Length, mm	Lens Status Preop PH, PS	BCVA Pre (Snellen)	Final BCVA (Snellen)	Preop Foveal Thickness, μm	Post Foveal Thickness, μm	Retinal Attachment	Hole Closure	Postoperative Complications
VG	M5	IX	29.10	28.50	PS	20/400	20/100	75	100	Yes	NA	None
PC	M4-M5	V	28.20	27.85	PH	20/80	20/50	65	130	Yes	NA	None
VG	M3	X			PH	20/100	20/40			Yes	NA	None
BA	M5	I	33.01	32.18	PS	20/400	20/125	15	15	Yes	NA	None
MM	M4	II	34.07	32.04	PS	20/50	20/40	345	185	Yes	NA	None
FC	M3	IV	28.53	27.10	PS	20/80	20/32	380	285	Yes	NA	None
MA	M4	I	30.49	29.71	PH	20/2,000	20/400	775	135	Yes	NA	None
BL	M4	VII	30.43	28.70	PH	20/200	20/200		320	Yes	NA	None
AL	M5	IV	27.54	26.78	PH	20/63	20/40	670	100	Yes	NA	None
BG	M4	VII + III	28.82	26.02	PH	20/125	20/125	300	145	Yes	NA	None
BA	M3-M4	II + III			PS	20/63	20/63	600	595	Yes	NA	None
FG	M4	V + III	29.86	28.42	PS	20/40	20/40	320	285	Yes	NA	None
CM	M3	V	29.10	28.5	PH	20/400	20/400	165	160	Yes	NA	None
ZML	M2	II			PH	20/100	20/25					None

*By Hsiang et al.¹⁵†By Curtin.¹⁶

NA, not applicable; PH, phakic; PS, pseudophakic.

BCVA change in eyes operated with buckle alone, for MF

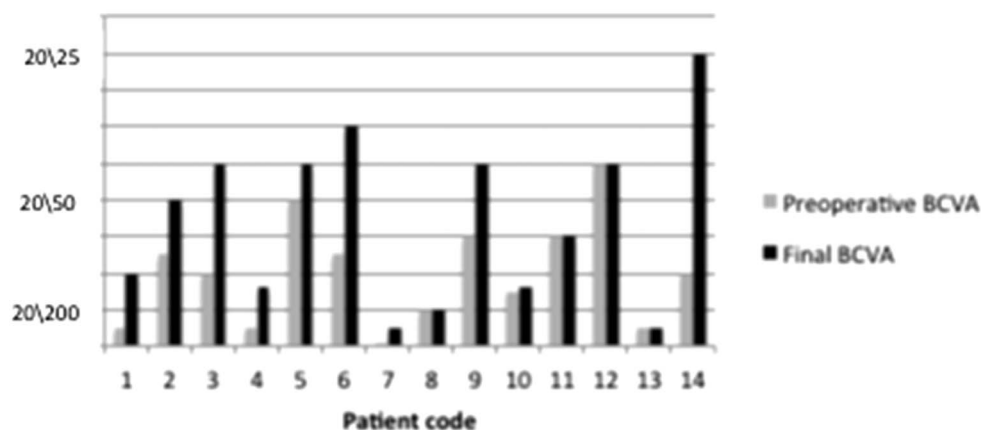


Fig. 11. The graph shows the BCVA change in each eye operated with the macular buckle alone for MF.

require posterior sutures or direct access to the posterior pole and allows direct visualization of the desired indentation site. In fact, no intraoperative complications were encountered.

Furthermore, the change in refraction and AL was limited because the indentation of the buckle induced more a flattening of the posterior staphyloma and not an inversion of the shape of the staphyloma, as happened instead in some previous buckle techniques. We recommend performing cataract surgery and IOL implantation after placing a macular buckle for more predictable IOL calculation.

The buckle was not well tolerated by every patient and had to be removed in 3 of 26 (11.5%)

eyes. The complications encountered in the study, such as erosion of the conjunctiva, diplopia, and in 1 case pain in the lateral movement, were linked to the presence of a large sponge material in the lateral arm (Figure 1). The new model with a solid silicone sleeve in the lateral arm allowed to avoid this complication and was better tolerated by the patients. In fact, all the cases of erosion and buckle removal were observed only with the first model of buckle with the lateral arm made with the silicone sponge.

Buckle dislocation and intraoperative misallocation, with the need of postoperative recentration, were overcome during the study by improving the placement modality and number of sutures in the lateral arm of the buckle and by inserting a fiber optic into the head of the buckle to allow transillumination through the microscope and a panoramic viewer.

OCT is a useful tool to understand the position of the macular buckle in relation to the macula; MRI is a useful imaging tool to better understand the position of the macular buckle, in relation to the optic nerve and the relocation of the posterior staphyloma.

In our series, the buckle obtained extremely good anatomical results, whether the buckle was combined with vitrectomy or when placed alone.

When the L-shaped macular buckle was used alone, in case of MD and of MF, the shape of the posterior staphyloma was flattened by the indentation of the buckle and most of the subretinal and/or intraretinal fluid disappeared during the first week postoperatively and disappeared completely later on. In some cases, residual tangential traction remained after buckling the macula and, when required by visual symptoms, was removed with secondary vitrectomy.

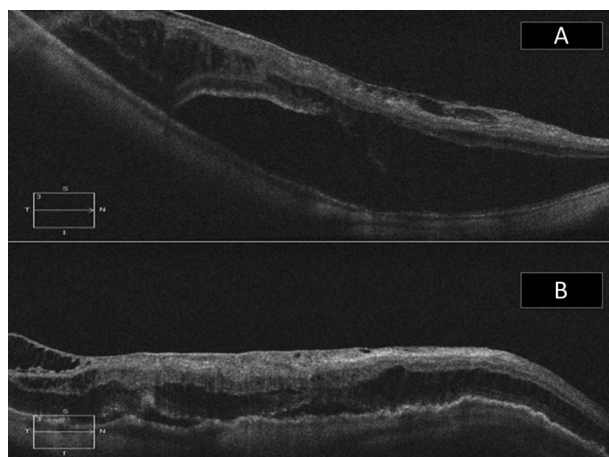


Fig. 12. **A.** Preoperative OCT of a high myopic eye, with macular detachment on the posterior staphyloma without macular hole. An epiretinal membrane exerts a tangential traction. **B.** OCT of the same eye, 8 weeks after insertion of a macular buckle (buckle group). The macular schisis and detachment are almost completely resolved. The retina, choroid, and sclera are flattened on the buckle. However, the epiretinal membrane still exerts tangential traction.

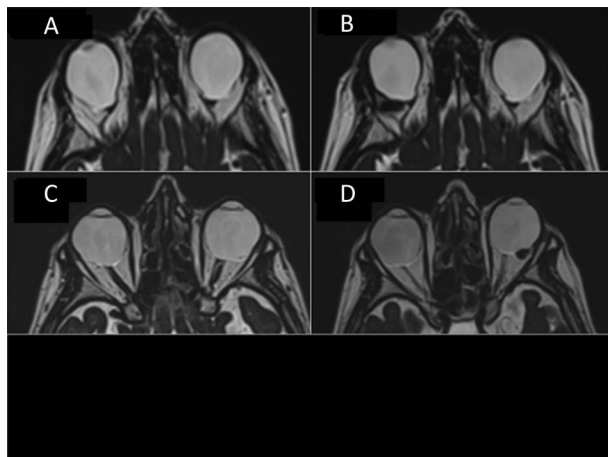


Fig. 13. **A.** T2 TSE axial magnetic resonance images of the orbits. The posterior contour of both globes is deformed in a macular and papillary staphyloma. **B.** T2 TSE axial magnetic resonance of the same patient, 1 month after the macular buckle implantation. The posterior wall of the right eye is flattened by the macular buckle. **C.** T2 TSE axial magnetic resonance images of the orbits of a different patient. The posterior contour of both globes is deformed in a macular staphyloma. The left eye, observed from the bottom, has a macular detachment. **D.** T2 TSE axial magnetic resonance of the patient in Figure 8C, 1 month after the macular buckle implantation. The posterior wall of the left eye is slightly convex on the macular buckle.

In cases of MHMD, the buckle alone, flattening the posterior sclera and resolving internal tractions, allowed not only to reattach the retina but also to effectively close the hole and therefore to improve vision in 60% of the patients.

The success of this surgery shows how the posterior staphyloma and the anteroposterior tractions play a very important role in the pathogenesis of the myopic traction maculopathy. It shows also that we

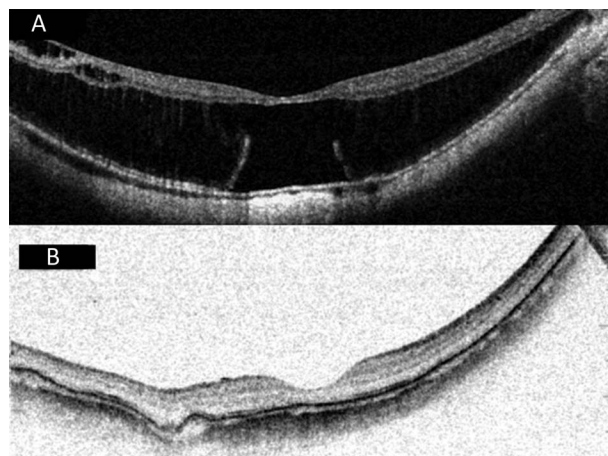


Fig. 14. **A.** Preoperative OCT of a high myopic eye, with macular detachment on the posterior staphyloma without macular hole. An epiretinal membrane exerts an extrafoveal tangential traction. **B.** OCT of the same eye, 2 years after the macular buckle implantation without vitrectomy (buckle group). The retina–choroid–sclera complex is flattened by the buckle and not convex. The macular detachment resolved and the tangential traction is no longer visible.

are primarily treating the detachment of the sclera from the retina more than the detachment of the retina from the sclera. A scleral detachment cannot be treated with endobulbar surgery.

In cases of MHMD and MD, the subretinal fluid was not intended to be actively drained. In fact, in these types of macular detachment, the amount of subretinal fluid is often limited and localized under the fovea. Any external drainage maneuver was considered too dangerous and not necessary.

The injection of a gas bubble was intended to favor the attachment of the retina to the retinal pigment epithelium in conjunction in the buckle group, but only in cases of MHMD. In fact, the patients who did not maintain facedown positioning had attached retinas but open holes. Hence, it seems that the indentation of the buckle may be sufficient to reattach the retina. However, the injection of a gas bubble and facedown positioning may be important to reach hole closure and a higher improvement in vision. Because the subretinal fluid in cases of MD and the intraretinal fluid in cases of MF disappeared slowly, the authors thought that the gas injection for these indications is likely unnecessary.

The combination of vitrectomy and buckle allowed to treat simultaneously tangential and anteroposterior tractions. The main advantages of this technique compared with vitrectomy alone were the ability to reattach the retina in MD and MHMD, the ability to close the hole in a high percentage of cases of MHMD, the ability to avoid relapse of retinal detachment in cases of MHMD, and finally the absence of iatrogenic macular hole in cases of MD and MF. This complication is well described when vitrectomy and ILM peeling are performed without buckling the macula.^{7,8}

Comparing the insertion of an L-shaped macular buckle alone to the combination of buckle plus vitrectomy plus vitreous cortex removal plus ILM peeling, plus endotamponade, the insertion of an L-shaped macular buckle alone was faster, safer, easier to perform and above all as effective. The main advantage, in cases of MD and MF, was that the buckle prevented the formation of an iatrogenic macular hole.^{7,8}

In conclusion, according to our experience and results, macular buckles are safe and well tolerated after a long follow-up. An L-shaped macular buckle is relatively easy to insert, after a learning curve and is associated with very low rate of complications. We propose to use macular buckle alone as the first procedure for all cases of the posterior staphyloma with secondary MTM.

We suggest using vitrectomy in combination with the macular buckle insertion or as a second-line

approach, only in cases of MF, MD, and MHMD displaying significant tangential traction, inducing metamorphopsia.

The authors are convinced that the presence of a macular buckle and a flattened posterior sclera lowers the risk of inducing an iatrogenic macular hole during vitrectomy with or without peeling of the ILM. The authors are moreover convinced that a good model of macular buckle could prevent all the long-term complications linked to the progressive worsening of the staphyloma such as atrophy of the retinal pigment epithelium.

This approach has changed the way of treating and resolving myopic tractional diseases.

Key words: posterior staphyloma, high myopia, macular buckle, macular foveoschisis, macular detachment, macular hole.

References

1. Takano M, Kishi S. Foveal retinoschisis and retinal detachment in severely myopic eyes with posterior staphyloma. *Am J Ophthalmol* 1999;128:472–476. Available at: <http://www.ncbi.nlm.nih.gov/pubmed/10577588>. Accessed January 18, 2015.
2. Kuhn F. Internal limiting membrane removal for macular detachment in highly myopic eyes. *Am J Ophthalmol* 2003;135:547–549. Available at: <http://www.ncbi.nlm.nih.gov/pubmed/12654379>. Accessed January 18, 2015.
3. Panozzo G, Mercanti A. Optical coherence tomography findings in myopic traction maculopathy. *Arch Ophthalmol* 2004;122:1455–1460.
4. Shimada N, Ohno-Matsui K, Baba T, et al. Natural course of macular retinoschisis in highly myopic eyes without macular hole or retinal detachment. *Am J Ophthalmol* 2006;142:497–500.
5. Gonvers M, Machemer R. A new approach to treating retinal detachment with macular hole. *Am J Ophthalmol* 1982;94:468–472. Available at: <http://www.ncbi.nlm.nih.gov/pubmed/7137271>. Accessed January 18, 2015.
6. Kanda S, Uemura A, Sakamoto Y, Kita H. Vitrectomy with internal limiting membrane peeling for macular retinoschisis and retinal detachment without macular hole in highly myopic eyes. *Am J Ophthalmol* 2003;136:177–180. Available at: <http://www.ncbi.nlm.nih.gov/pubmed/12834688>. Accessed January 18, 2015.
7. Ikuno Y, Sayanagi K, Ohji M, et al. Vitrectomy and internal limiting membrane peeling for myopic foveoschisis. *Am J Ophthalmol* 2004;137:719–724.
8. Panozzo G, Mercanti A. Vitrectomy for myopic traction maculopathy. *Arch Ophthalmol* 2007;125:767–772.
9. Shukla D, Dhawan A. Foveoschisis after vitrectomy for myopic macular hole with secondary retinal detachment. *Eye (Lond)* 2009;23:2124–2125.
10. Mete M, Parolini B, Maggio E, Pertile G. 1000 cSt silicone oil vs heavy silicone oil as intraocular tamponade in retinal detachment associated to myopic macular hole. *Graefes Arch Clin Exp Ophthalmol* 2011;249:821–826.
11. Ripandelli G, Coppé AM, Fedeli R, et al. Evaluation of primary surgical procedures for retinal detachment with macular hole in highly myopic eyes: a comparison [corrected] of vitrectomy versus posterior episcleral buckling surgery. *Ophthalmology* 2001;108:2258–2264; discussion 2265. Available at: <http://www.ncbi.nlm.nih.gov/pubmed/11733267>. Accessed January 12, 2015.
12. Theodossiadis GP, Sasoh M. Macular buckling for retinal detachment due to macular hole in highly myopic eyes with posterior staphyloma. *Retina* 2002;22:129. Available at: <http://www.ncbi.nlm.nih.gov/pubmed/11884899>. Accessed January 18, 2015.
13. Theodossiadis GP, Theodossiadis PG. The macular buckling procedure in the treatment of retinal detachment in highly myopic eyes with macular hole and posterior staphyloma: mean follow-up of 15 years. *Retina* 2005;25:285–289. Available at: <http://www.ncbi.nlm.nih.gov/pubmed/15805904>. Accessed January 12, 2015.
14. Parolini B, Frisina R, Pinackatt S, Mete M. A new L-shaped design of macular buckle to support a posterior staphyloma in high myopia. *Retina* 2013;33:1466–1470.
15. Hsiang HW, Ohno-Matsui K, Shimada N, et al. Clinical characteristics of posterior staphyloma in eyes with pathologic myopia. *Am J Ophthalmol* 2008;146:102–110.
16. Curtin BJ. The posterior staphyloma of pathologic myopia. *Trans Am Ophthalmol Soc* 1977;75:67–86. Available at: <http://www.pubmedcentral.nih.gov/articlerender.fcgi?artid=1311542&tool=pmcentrez&rendertype=abstract>. Accessed January 18, 2015.
17. Schepens CL, Okamura ID, Brockhurst RJ. The scleral buckling procedures. I. Surgical techniques and management. *AMA Arch Ophthalmol* 1957;58:797–811. Available at: <http://www.ncbi.nlm.nih.gov/pubmed/13478226>. Accessed January 18, 2015.
18. Rosengren B. The silver plomb method in amotio retinae: clinical experience and results. *Bibl Ophthalmol* 1966;70:253–256. Available at: <http://www.ncbi.nlm.nih.gov/pubmed/5331047>. Accessed January 18, 2015.
19. Klöti R. Silver clip for central retinal detachments with macular hole. *Mod Probl Ophthalmol* 1974;12:330–336. Available at: <http://www.ncbi.nlm.nih.gov/pubmed/4419789>. Accessed January 18, 2015.
20. Siam AL. Management of central retinal detachment due to a macular hole. *Br J Ophthalmol* 1973;57:351–354. Available at: <http://www.pubmedcentral.nih.gov/articlerender.fcgi?artid=1214900&tool=pmcentrez&rendertype=abstract>. Accessed January 18, 2015.
21. Ando F, Ohba N, Touura K, Hirose H. Anatomical and visual outcomes after episcleral macular buckling compared with those after pars plana vitrectomy for retinal detachment caused by macular hole in highly myopic eyes. *Retina* 2007;27:37–44.
22. Mateo C, Burés-Jelstrup A, Navarro R, Corcóstegui B. Macular buckling for eyes with myopic foveoschisis secondary to posterior staphyloma. *Retina* 2012;32:1121–1128.
23. Baba T, Tanaka S, Maesawa A, et al. Scleral buckling with macular plombe for eyes with myopic macular retinoschisis and retinal detachment without macular hole. *Am J Ophthalmol* 2006;142:483–487.
24. Zhu Z, Ji X, Zhang J, Ke G. Posterior scleral reinforcement in the treatment of macular retinoschisis in highly myopic patients. *Clin Experiment Ophthalmol* 2009;37:660–663.
25. Stirpe M, Ripandelli G, Rossi T, et al. A new adjustable macular buckle designed for highly myopic eyes. *Retina* 2012;32:1424–1427.