



In this RWC column we will discuss:

- The Korean Retina Society;
- Macular Indentation to Manage Complications of Pathological Myopia;
- Fibrin Glue-Assisted Hemostasis for Persistent Intraoperative Optic Nerve Bleeding;
- Submacular Hemorrhage: How Do You Manage?;
- Valsalva Retinopathy Drained with YAG Laser; and
- The EmPuzzled Eye.

Kourous Rezaei, MD, President
Ashish Sharma, MD, Committee Co-Chair
Lihteh Wu, MD, Committee Co-Chair

RWC GLOBAL SOCIETY PARTNER **KOREAN RETINA SOCIETY**

The Korean Retina Society (KRS) is a dynamic organization representing fellowship-trained retina specialists dedicated to advancing research and clinical practices of vitreoretinal diseases in South Korea.



KRS actively encourages collaboration, networking, and advocates for the latest advancements in the field. Bolstering its mission, the society forges innovative partnerships with retina societies worldwide, fostering progress in education and research.

KRS operates under the guidance of a Board of Directors, with the support of committee members. Dr. June Gone Kim currently leads the society as President.

To facilitate knowledge dissemination and enhance member engagement, KRS has launched its official publication, *Journal of Retina* (<https://www.e-retina.or.kr/main.html>). This biannual, open-access journal is committed to publishing articles related to retinal and vitreous research.

Over the years, KRS has hosted symposiums, inviting renowned speakers from around the world to enlighten and stimulate Korean retina specialists and gain insight into the latest developments in the field. Through regular symposiums, workshops, and academic conferences, KRS provides a platform for the exchange of ideas and insights among its members. Its annual meeting is scheduled for December 15-17, 2023, in Seoul, Korea and will bring together Korean retina specialists and internationally recognized experts to exchange ideas, deliberate, and explore the latest advancements. For more information, visit <https://retina.or.kr/eng/sub01.html>.

RETINA WORLD CONGRESS VIDEO GALLERY CASE OF THE MONTH

Fibrin Glue-Assisted Hemostasis for Persistent Intraoperative Optic Nerve Bleeding

Submitted by: Mudit Tyagi, MD; Srishti Ramamurthy, MD, LV Prasad Eye Institute, Hyderabad, India
<https://retinaworldcongress.org/surgical/fibrin-glue-hemostasis-for-persistent-intraoperative-optic-disc-bleed/>

A 26-year-old man, a follow-up case of occlusive vasculitis, presented with sudden diminution of vision in the right eye due to vitreous hemorrhage. The right eye had previously undergone panretinal laser photocoagulation for proliferative vascular retinopathy with previously documented vision of 20/30. At the time of presentation, the patient's visual acuity in the eye had dropped from 20/30 to 20/400.

A 25-gauge pars plana vitrectomy was performed. Following membrane dissection, persistent intraoperative bleeding from the disc was noted. Infusion pressure was raised to 60 mmHg to control intraoperative optic nerve bleed. The bleeding persisted despite multiple attempts of elevating intraocular pressure and fluid air ex-

change. Fibrin glue was injected over the disc to control the bleed. Under air, one drop of the thick component (thrombin) of glue was injected with a 1-cc tuberculin syringe. The thin component (fibrinogen) was injected in a controlled manner using a microdose injector connected to viscous fluid injection mode on the vitrectomy machine. After 3 minutes, a polymerized gel-coagulum was formed which was repositioned over the disc with a flute needle to prevent further bleed. Air-fluid exchange was done and the case was closed under normal saline.

Hemostasis was achieved using fibrin glue, and visual acuity improved to 20/20 at 1 week follow up and a complete resorption of the gel-coagulum was noted within 1 week.

doi: 10.3928/23258160-20231101-01



HOT TOPIC IN THE WORLD OF RETINA

Submacular Hemorrhage: How Do You Manage?

Submitted by: Leandro Cabral Zacharias, MD, PhD, University of Sao Paulo Medical School, Sao Paulo, Brazil; Manish Nagpal, MD, Retina Foundation and Eye Research Centre, Ahmedabad, India; Sophie Bakri, MD, Mayo Clinic, Rochester, Minnesota

The management of patients with submacular hemorrhage (SMH) is a controversial area. In addition to a lot of revolution in this area over the years, there has been a decline in SMH since the introduction of anti-vascular endothelial growth factor (VEGF) therapy.

There is no formal consensus on the management of SMH, as it is very difficult to perform clinical trials in this area. Therefore, personal experience is key to guiding the management. Below is the opinion of our experts who have significant experience in handling these cases.

Leandro Cabral Zacharias, MD, PhD, University of Sao Paulo Medical School, Sao Paulo, Brazil. SMH is an acute and rare vision-threatening complication, most commonly related to age-related macular degeneration (AMD), retinal macroaneurysm, or trauma. Without proper treatment, visual outcomes are poor, as subretinal hemosiderin, photoreceptor traction by fibrin or clot retraction, and physical separation of the neurosensory retina from the retinal pigment epithelium (RPE) lead to photoreceptor loss and subretinal fibrosis formation.

Cases of submacular retinal hemorrhage (SRH) were excluded from most pivotal anti-VEGF trials, so until recently, treatment evidence came from case series and personal experience.

In addition to anti-VEGF treatment, subretinal clot mobilization is imperative for visual acuity (VA) recovery. Some variables, described here, may play a key role on how to approach SRH.

- SRH below or above RPE: Sub-RPE hemorrhages cannot be mobilized and bring a worse visual prognosis, therefore I always try to perform optical coherence tomography (OCT) to determine proper blood location.
- Clot thickness: Thin hemorrhage (less than 100 μm) may be treated with intravitreal injections only.
- Foveal involvement: For me, there is no reason to mobilize blood if the fovea is spared.
- Location: Mobilization may be challenging if most of the hemorrhage is located at the superior macula.
- Duration of symptoms: Intervention sooner rather than later is ideal. After 2 weeks of symptoms, there may be definitive tissue damage precluding any surgical intervention.

I tend to indicate early intervention aiming to mo-

bilize the blood, associated with anti-VEGF treatment, in cases of thick SMH with foveal involvement. My preferred approach is to perform pars plana vitrectomy followed by subretinal injection of 0.1 to 0.2 mL of tissue plasminogen activator (tPA) (25 $\mu\text{g}/0.1\text{mL}$) with a 41-gauge cannula, no attempt to evacuate blood, partial fluid air exchange, anti-VEGF injection at the end of the procedure and postoperative prone head positioning.

As cases of SMH frequently happen in the very old population, clearing those for surgery on short notice may be tricky. In those cases, I tend to advise pneumatic displacement, with or without intravitreal tPA. Recent literature supports the latter approach: The Manchester Protocol tested a step-wise approach to deal with SMH, consisting of intravitreal C3F8 and tPA, followed by prompt vitrectomy with subretinal tPA if failure to displace blood was observed on postoperative day 3. Pneumatic displacement had a 77% success rate in this series.¹ Another recent prospective series with 78 patients failed to show a difference in VA gain between pneumatic displacement and vitrectomy with subretinal tPA—both approaches led to VA gain.²

In conclusion, SMH cases tend to have severe visual loss without treatment. My personal preference is to indicate early intervention with vitrectomy and subretinal tPA. However, a step-wise approach, as proposed by the Manchester Protocol, may be considered as an alternative, especially if the patient is not cleared for surgery.

Manish Nagpal, MD, Retina Foundation and Eye Research Centre, Ahmedabad, India. SMH is a potentially blinding condition and needs to be managed as early as possible. If there is a delay in management, it usually leads to a lot of central disciform scarring. I perform OCT, fluorescein, and indocyanine green angiography as a baseline on presentation to get a full understanding of the extent and cause of the hemorrhage. It also helps in choosing the most suited anti-VEGF: If the cause is idiopathic polypoidal choroidal vasculopathy (IPCV), then the choice would be aflibercept (Eylea, Regeneron, USA); otherwise, I would go with ranibizumab (Lucentis, Novartis, USA).

For ease of understanding and management, I divide them into three categories: small (1-2 disc diameter), medium (2-5 DD), and large (beyond 5DD with retinal detachment). For the small category, I treat with anti-VEGF injections and gas tamponade to get faster



clearance from the macular area. For the medium and large categories, I typically use surgical management.

For the medium category, I perform a vitrectomy and make a smile-shaped retinectomy within the arcades at the most elevated portion of the hemorrhage. After that, I evacuate the whole hemorrhagic complex, including the neovascular membrane in toto, by using controlled suction on the cutter. After that, I do the air-fluid exchange, and endolaser to the retinectomy, and gas.

For the large category, I do a vitrectomy and make a peripheral large retinectomy (270°), which is planned based on the extent of the hemorrhage. Most hemorrhages have a retinal elevation and after the retinectomy, it is easy to elevate the remaining retina. After that, I evert the cut retinal flap, which behaves like a giant retinal tear, to expose the whole content of SMH along with the neovascular membrane. This is gradually eaten up using the cutter. Once the hemorrhage is cleared, I revert the retinal flap just like a giant retinal tear, do 360° endolaser, and put silicon oil.

For all the surgical cases, I use tPA intravitreally a day before the surgery to maximize liquefaction of the submacular complex. During surgery, I ensure a thorough vitrectomy, followed by posterior vitreous detachment creation and vitreous removal up to the periphery before doing the retinectomy. This is to reduce any chance of retinal detachment and proliferative vitreoretinopathy since retinectomies are carried out. For the large retinectomies, I also use chandelier illumination, which helps in doing bimanual maneuvers while everting the retinal flap with forceps and evacuating the hemorrhagic complex with the cutter simultaneously.

For the small category, I continue to use anti-VEGF injections until complete drying on the OCT and continue to follow up. For surgical removals, I have rarely had to use anti-VEGF as the whole neovascular complex is evacuated during the surgical process.

Sophie Bakri, MD, Mayo Clinic, Rochester, Minnesota, USA. SMH can be caused by various etiologies such as choroidal neovascularization (CNV), retinal arterial microaneurysms, and trauma. The risk of SMH is higher in patients taking anticoagulants, particularly warfarin and clopidogrel. Based on the location, SMH can be classified as subretinal or sub-RPE. Size and thickness also play a key role in deciding the management. A small subretinal hemorrhage is the size of few disc diameters around the fovea, a medium-sized hemorrhage reaches up to arcades, and a massive subretinal hemorrhage (also known as a hemorrhagic retinal detachment) often involves the retinal periphery. Based on the thickness, I divide them into less than

500 microns (thin) or more than 500 microns (thick) based on the OCT. The duration of SMH is also important in the management decision.

I agree with Dr. Zacharias that SMH may cause retinal damage through a number of mechanisms if management is delayed by more than 14 days.^{3,4} This underscores the importance of early management. I agree with Dr. Nagpal that for small thin SMH or those not involving the fovea, I initiate treatment with anti-VEGF therapy. For medium-sized SMH, I advise surgical displacement by vitrectomy, subretinal tPA, and air-fluid exchange. However, as mentioned earlier, the hemorrhage should be thick, involve the fovea, and look fresh or have occurred within approximately 2 weeks to be a candidate for the surgery. If I think the patient would not benefit from surgery due to various factors (eg, chronicity, visual potential), I would treat with anti-VEGF therapy. Large SMH with hemorrhagic retinal detachment represent a difficult challenge. It is important to check that the international normalised ratio is within the recommended range in patients taking warfarin. I sometimes offer patients retinal surgery with vitrectomy, 180-degree peripheral retinectomy, removal of the CNV, and silicone oil tamponade.

Many groups have proposed a variety of therapeutic options for medium-sized SMH. These include pneumatic displacement with or without tPA and surgery, as in the Submacular Surgery Trials⁵ (SST), which includes vitrectomy with removal of the neovascular complex and blood, rather than hemorrhage displacement. Pneumatic displacement without liquefaction of the blood may cause shearing of the photoreceptors, and the SST was performed before anti-VEGF agents were available and was associated with complications such as retinal detachment.

For patients who undergo surgical intervention, postoperative management depends on the etiology of the SRH. If it is due to CNV, then diagnostic imaging should be performed, including fluorescein angiography and OCT, and treatment of the CNV should be performed with currently available agents, including anti-VEGF agents, photodynamic therapy, or combination therapies.

In these cases, the outcome is difficult to predict due to various factors, such as preexisting geographic atrophy, fibrosis, and many more. For example, if SMH is due to retinal arterial macroaneurysm, then it would have a better prognosis compared to patients with CNV associated with AMD.

Overall, I think that with newer pharmacological and surgical advances, we are better prepared to handle these situations than ever before.



RETINA ROCKS IMAGE GALLERY CASE OF THE MONTH

Valsalva Retinopathy Drained with YAG Laser

Submitted by: Shivraj Tagare, DNB; Nishant Maindargi, MBBS; Aravind Eye Hospital, Pondicherry, India

A 37-year-old man presented after sudden vision loss in his right eye following vigorous coughing. Vision was 20/400 in his right eye and 20/20 in his normal left eye.

Fundus examination of his right eye showed scattered posterior pole retinal hemorrhages and a large sub-internal limiting membrane (ILM) hemorrhage obscuring his right macula. A Nd:YAG laser was used to create a small inferior opening in the ILM. Fundus photography shows that the blood immediately started to drain into the inferior vitreous (Figure 1).

Valsalva retinopathy is characterized by usually unilateral retinal and preretinal hemorrhages caused by raised intrathoracic or intraabdominal pressure. Various causes include coughing, heavy lifting, and vomiting. These hemorrhages almost always resolve without sequelae, although in severe cases, the sub-ILM blood can be drained into the inferior vitreous

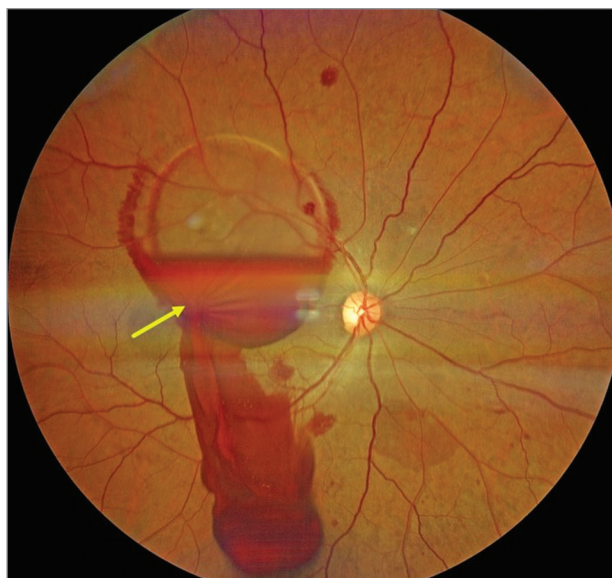


Figure 1. Valsalva retinopathy hemorrhage draining into the inferior vitreous immediately following YAG laser to the inferior internal limiting membrane (arrow).

by creating a small ILM opening using either a thermal or Nd:YAG laser as was done for this patient.

This case is from the Retina World Congress' Retina Rocks (<https://www.retinarocks.org>), the world's largest online, open-source image gallery and reference library.

REFERENCES

1. Chew GWM, Ivanova T, Patton N, et al. Step-wise approach to the management of submacular hemorrhage using pneumatic displacement and vitrectomy: the Manchester Protocol. *Retina*. 2022;42(1):11-18. <https://doi.org/10.1097/IAE.0000000000003294> PMID:34469407
2. Gabrielle PH, Delyfer MN, Glacet-Bernard A, et al. Surgery, tissue plasminogen activator, antiangiogenic agents, and age-related macular degeneration study: a randomized controlled trial for submacular hemorrhage secondary to age-related macular degeneration. *Ophthalmology*. 2023;130(9):947-957. <https://doi.org/10.1016/j.ophtha.2023.04.014> PMID:37088447
3. Glatt H, Machemer R. Experimental subretinal hemorrhage in rabbits. *Am J Ophthalmol*. 1982;94(6):762-773. [https://doi.org/10.1016/0002-9394\(82\)90301-4](https://doi.org/10.1016/0002-9394(82)90301-4) PMID:7180915
4. Toth CA, Morse LS, Hjelmeland LM, Landers MB III. Fibrin directs early retinal damage after experimental subretinal hemorrhage. *Arch Ophthalmol*. 1991;109(5):723-729. <https://doi.org/10.1001/archopht.1991.01080050139046>
5. Bressler NM, Bressler SB, Childs AL, et al.; Submacular Surgery Trials (SST) Research Group. Surgery for hemorrhagic choroidal neovascular lesions of age-related macular degeneration: ophthalmic findings: SST report no. 13. *Ophthalmology*. 2004;111(11):1993-2006. <https://doi.org/10.1016/j.ophtha.2004.07.023> PMID:15522364

LCZ is a speaker for Roche and Bayer. MN is a consultant for Alcon. SB has been a consultant for Abbvie, Adverum, Allergan, Amgen, Annexon, Apellis, Aviceda, Chologene, Eyepoint, ilumen, Iveric bio, Kala, Genentech, Neurotech, Novartis, Ocular Therapeutix, Outlook, Pixium, Regenxbio, Regeneron, Rejuvitas, Revana, Roche, VoxelCloud, and Zeiss.



RETINA ROCKS IMAGE GALLERY 2023 CASE OF THE YEAR

The EmPuzzled Eye

Submitted by: Veronika Matello; Barbara Parolini, MD, Eyecare Clinic, Brescia, Italy

Figure 1 is a collage of different widefield B-scan optical coherence tomography (OCT; Canon, Xephilio, S1, Japan) images from different patients. The authors reconstructed the entire profile of an eye, with a collage of peculiar cases.

The cases are described as follows, starting from the cornea and going clockwise:

1. Cornea transplant;
2. Iris bombe for sinechiae between iris and intracocular lens (IOL);
3. IOL in the bag;
4. Peripheral OCT in an eye with branch retinal vein occlusion and peripheral retinal new vessels. The red color indicates the blood flow in the retina and into the preretinal lesion;
5. Posterior pole of a highly myopic eye with macular staphyloma and myopic traction maculopathy stage 2b with macular schisis and inner lamellar macular hole;
6. Optic nerve drusen;
7. Chronic retinal detachment and subretinal fluid;
8. Peripheral retinoschisis with elevated inner retinal layer and folded outer retinal layer corresponding to the edge of an external retinal break.

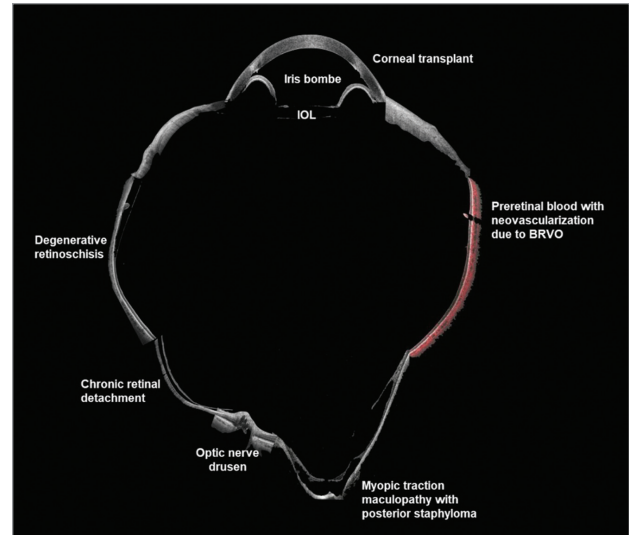


Figure 1. Collage of different widefield B-scan optical coherence tomography (Canon, Xephilio, S1, Japan) images from different patients.

This image is a tribute to what new instrumentation can offer. New technology will guide clinicians in the pathway of knowledge, where the more we see, the more we can do and help our patients.

The authors are deeply grateful to the RWC and the journals for the prestigious recognition.